Л.Л. Колесников
Д.Б. Никитюк
С.В. Клочкова
И.Г. Стельникова

# АНАТОМИЯ ЧЕЛОВЕКА

## УЧЕБНИК НА АНГЛИЙСКОМ ЯЗЫКЕ

**В ТРЕХ ТОМАХ**

Министерство образования и науки РФ
Рекомендовано ГБОУ ВПО «Первый Московский государственный медицинский университет имени И.М. Сеченова» в качестве учебника для студентов учреждений высшего профессионального образования, обучающихся по специальностям «Лечебное дело», «Педиатрия» по дисциплине «Анатомия»

**Москва**
**ИЗДАТЕЛЬСКАЯ ГРУППА**
**«ГЭОТАР-Медиа»**
**2018**

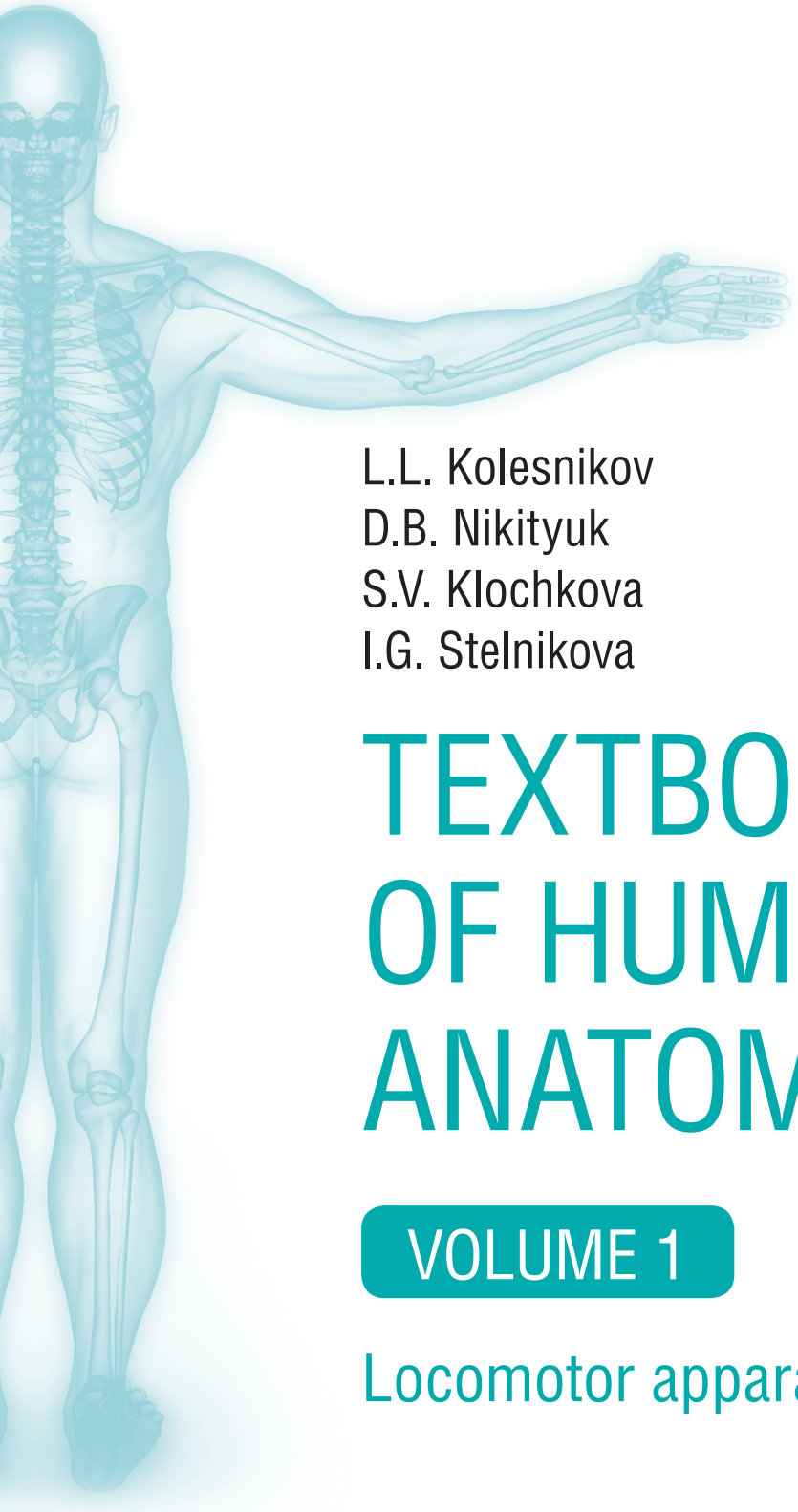

L.L. Kolesnikov
D.B. Nikityuk
S.V. Klochkova
I.G. Stelnikova

# TEXTBOOK OF HUMAN ANATOMY

## VOLUME 1

## Locomotor apparatus

Moscow
«GEOTAR-Media»
PUBLISHING GROUP
2018

# STRUCTURAL ORGANIZATION OF THE HUMAN BODY

The human body is composed of cells and non-cellular structures which consistently united in tissues, organs, organs' systems and the human body as a whole during the process of philo- and ontogenesis. A *cell* (*cellula*) is an elementary genetic, structural and functional unit, the main structural element of all living organisms (Fig. 5). A surface apparatus, cytoplasm and nucleus are the components of a human body cell.

The surface apparatus of a cell includes the cell membrane, *surface specializations* (*specialisationes superficiales*) or the supramembrane complex and submembrane structures. The *cell membrane*, *plasmalemma* (*membrana cellularis*, *plasmalemma*) is composed of the biphospholipid layer and protein molecules which are either on its surface or penetrate it (Fig. 6). Intracellular membranes have a similar structure. A supramembrane layer is termed the *glycocalyx* (*glycocalyx*) consisting of carbohydrate molecules (residue) associated with the proteins. This is a receptor unit of a cell. A submembrane complex is formed by an *ectocytoplasm*, *cortical cytoplasm* (*ectocytoplasma*) which contains microtubules and microfilaments composed of protein structures that act as the cytoskeleton. The surface apparatus of a cell provides the transmembrane transport of substances into and out of the cell.

The *cytoplasm* (*cytoplasma*) contains the *cytosol* (*cytosol*, *matrix cytoplasmatica*), *organelles and cytoplasmic inclusions* (*organella et inclusiones cytoplasmicae*). The cytosol is a colloidal solution, the internal environment of the cell where all metabolic reactions occur. The organelles are permanent struc-

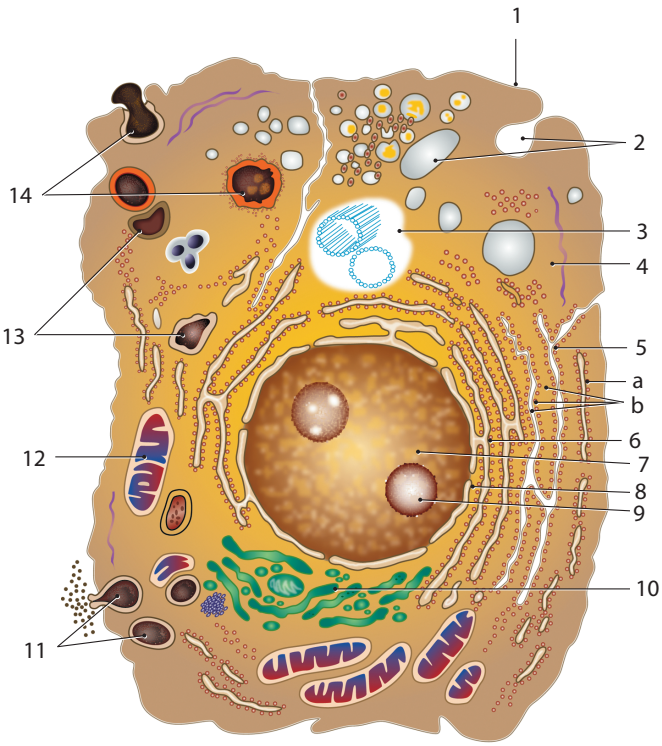


**Fig. 5.** Structural organization and some principal organelles of a typical cell: 1 — cell membrane (plasmalemma); 2 — pinocytotic vesicles; 3 — centrosome (cytocentre); 4 — cytoplasm; 5 — endoplasmic reticulum: a — membrane of a rough endoplasmic reticulum, b — ribosomes; 6 — connection of the perinuclear space with endoplasmic cavities; 7 — nucleus; 8 — nuclear pores; 9 — nucleolus; 10 — Golgi apparatus (complex); 11 — secretory vacuoles; 12 — mitochondrion; 13 — lysosomes; 14 — stages of phagocytosis

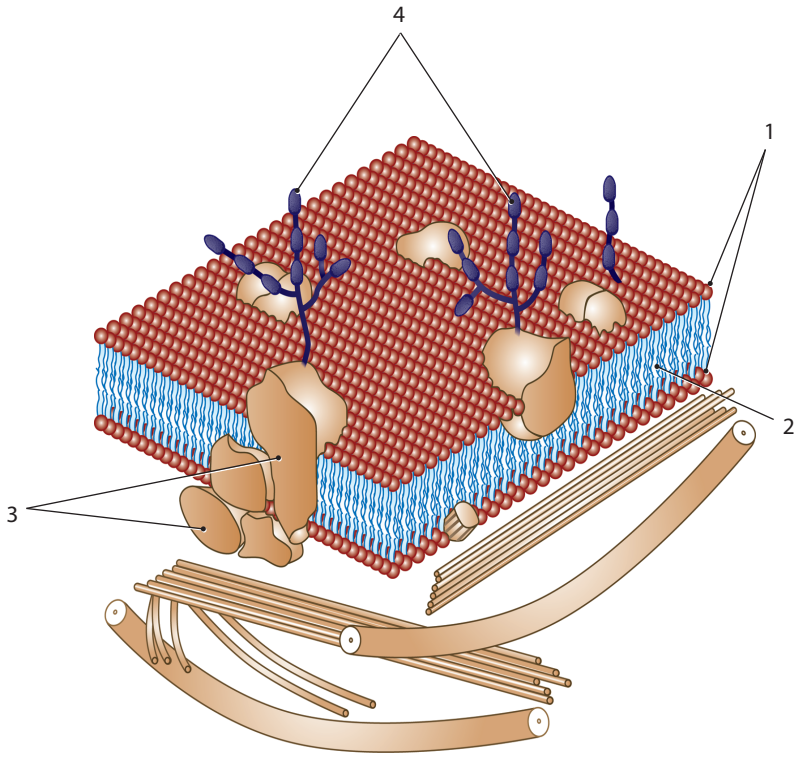


**Fig. 6.** Molecular organization of a cell membrane (plasmalemma): 1 — phospholipids; 2 — hydrophobic tails of phospholipids; 3 — proteins; 4 — glycolipids of glycocalix

tures of a cell; they have a specific structure and perform certain functions. They include the ribosomes, endoplasmic reticulum, Golgi complex, lysosomes, peroxysomes, mitochondria, cytocentre (centrosome).

*Ribosomes* (*ribosomae*) are the organelles carrying out protein synthesis. Large groups of the ribosomes are called *polysomes* (*polyribosomae*). Ribosomes are joined with the walls of the endoplasmic reticulum which are formed by membranes and receive synthesized proteins.

An *endoplasmic reticulum* (*reticulum endoplasmicum*) is the main highway of the intracellular transport. The part with the ribosomes is called the *rough endoplasmic reticulum* (*reticulum endoplasmicum granulosum*). The other part which is free from ribosomes is named the smooth endoplasmic reticulum (*reticulum endoplasmicum non granulosum*). It synthesizes carbohydrates and lipids. A tubular content comes into the Golgi complex.

The *Golgi complex*, *Golgi apparatus* (*complexus golgiensis*, *apparatus golgiensis*) is composed of vesicles, saccules and tubules, their walls are formed by the membrane. Synthesis products are «packaged» there and then go into the cytoplasm and are used by a cell or are evacuated from it.

The cell membrane, endoplasmic reticulum and Golgi complex constitute a common cell membrane system.

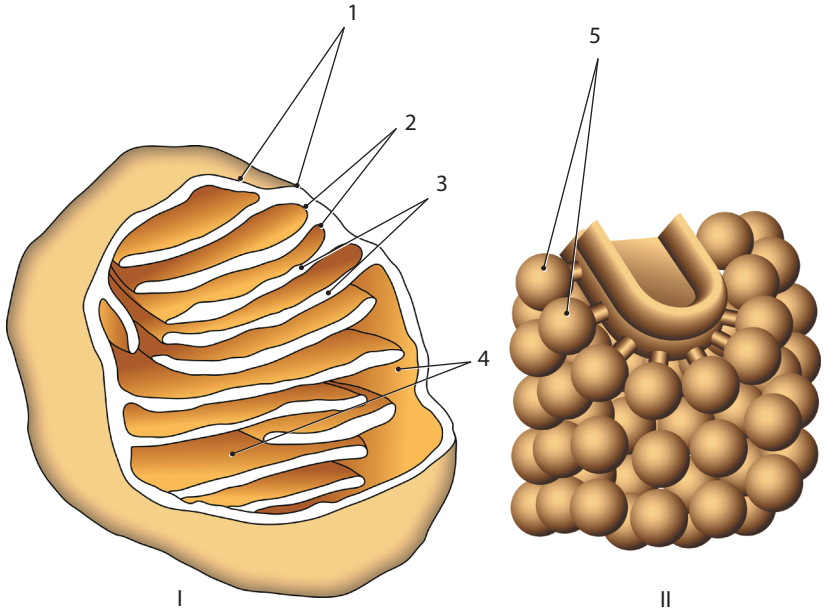


**Fig. 7.** The Mitochondrion: I — principal scheme: 1 — external mitochondrial membrane; 2 — internal mitochondrial membrane; 3 — cristae; 4 — mitochondrial matrix; II — the scheme of a mitochondrial crista: 5 — elementary particles (particula fungiformis)

*Lysosomes* (*lysosomae*) are separated from Golgi complex and contain up to 60 hydrolytic enzymes. *Peroxysomes* (*peroxysomae*) are similar to lysosomes and hold about 40 enzymes transforming peroxydes, particularly hydrogen peroxide.

Metabolic processes are provided with the energy of adenosine triphosphate (ATP) which is synthesized in the *mitochondria* (*mitochondria*) (Fig. 7). The *mitochondrion* (*mitochondrion*) is the energy plant of the cell.

Cell division involves *centrioles* (*centriola*) of a cytocentre (centrosome). These two cylindrical structures form the centres of the daughter cells and compose a *mitotic spindle* (*fusus mitoticus*) of the cell division apparatus.

**Cytoplasmic inclusions** are not always present in the cytoplasm, yet are considered a normal part of the cell. There are stored food (carbohydrates, lipids) and cell pigments (exogenous, endogenous) inclusions.

The *nucleus* (*nucleus*) has a different shape and is comprised of the nuclear envelope, nucleoplasm, nucleolus (Fig. 8).

The *nuclear envelope* (*tegumentum nucleare*) is the limited structure that compartmentalizes the contents of the nucleus, segregating them from the cytoplasm. It consists of the *outer* and *inner nuclear membranes* (*membranae nucleares externa* et *interna*) with unique bidirectional access sites called *nuclear pores* (*porus nuclearis*).

The *nucleoplasm*, *karyoplasm* (*nucleoplasma*) is composed of the *fibrous lamina* (*lamina fibrosa nuclearis*), *chromatin* (*chromatinum*), *nuclear body* (*corpusculum nucleare*).

A *nucleolus* (*nucleolus*) has got the *nucleolonema* (*nucleolonema*) with the *amorphous part* (*pars*



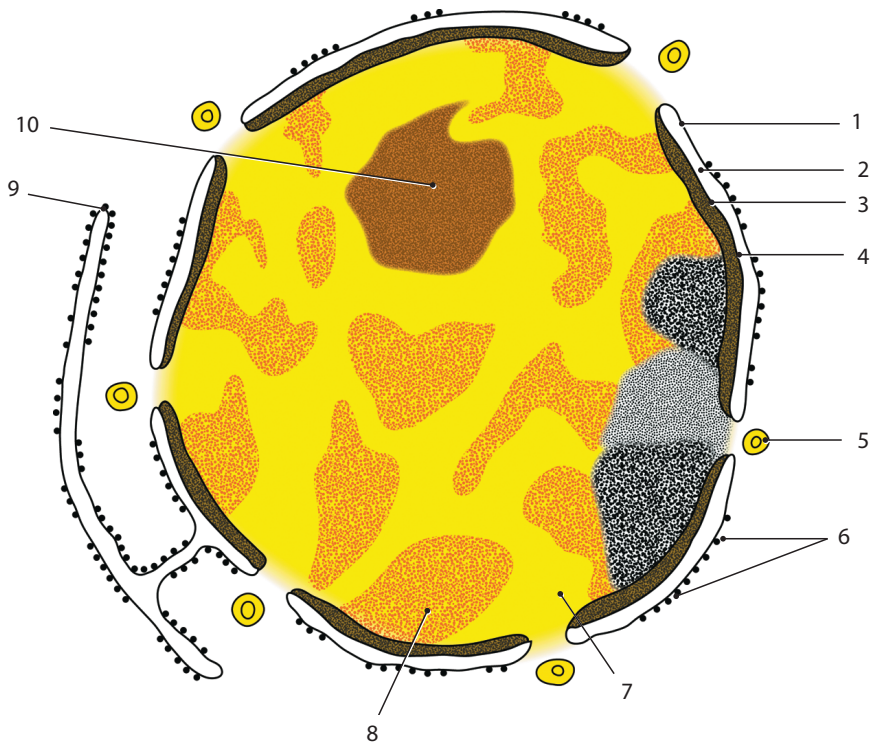


**Fig. 8.** The nucleus: 1 — outer nuclear membrane (of a nuclear envelope); 2 — perinuclear space; 3 — inner nuclear membrane (of a nuclear envelope); 4 — nuclear lamina (fibrous lamina); 5 — nuclear pore complex; 6 — ribosomes; 7 — nucleoplasm (karyoplasm); 8 — chromatin; 9 — cistern of a granular endoplasmic network; 10 — nucleolus

*amorpha*), *nucleolar chromatin* (*pars chromatoidea*), *fibrous region* (*pars fibrosa*), *granular component* (*pars granulosa*).

The nucleus contains almost all the cell's deoxyribonucleic acid (DNA). The DNA stored within the nucleus is essential to the cell because its genes encode the amoni acid sequences of the various proteins that the cell must produce to stay alive. Each DNA molecule is coiled, supercoiled, and looped in an elaborate manner so as to constitute a thread-shaped structure called a chromosome. During mitosis (Gr., *mitosis*, thread-like condition), each chromosome becomes microscopically visible as an individual thread that stains intensely with hematoxylin (Gr., *chroma*, color; *soma*, body) (Fig. 9). During the greater part of the cell's lifespan, chromosomes are typically indistinguishable as separate entities because they exist in a partly



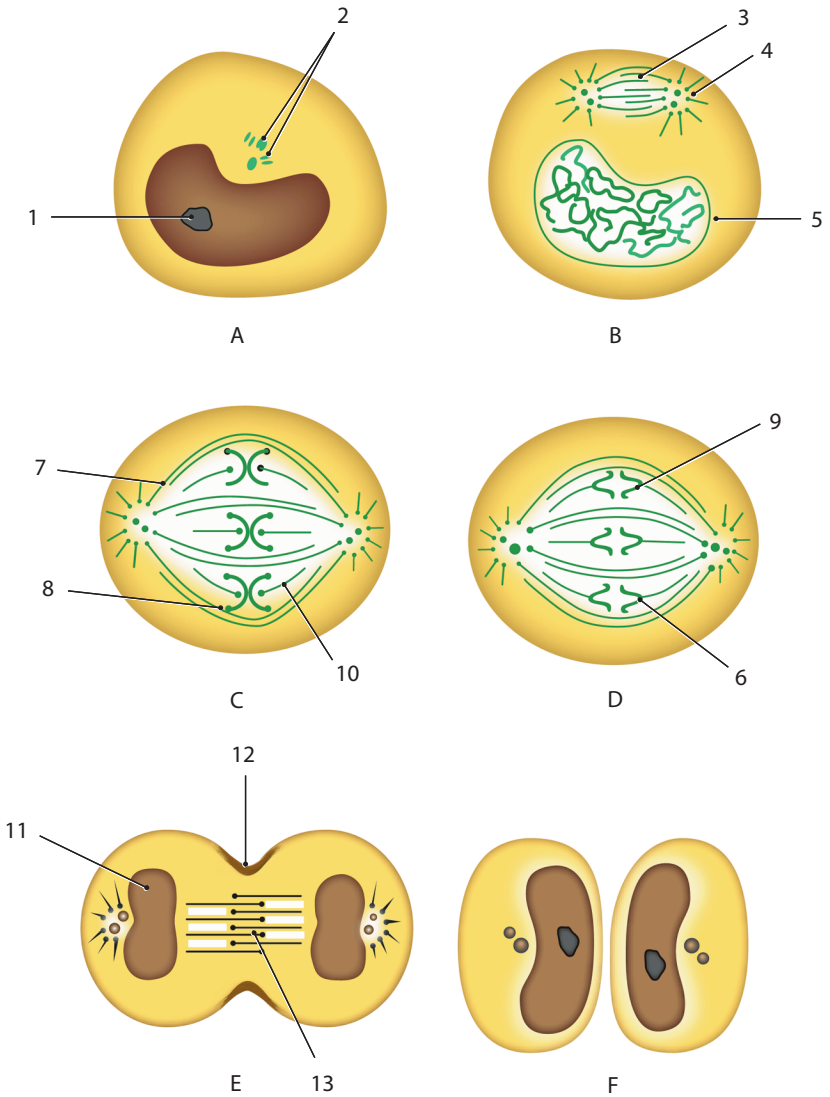


**Fig. 9.** The scheme of mitosis: A — interphase; B — prophase; C — metaphase; D — anaphase; E — telophase; F — two new cells; 1 — nucleolus; 2 — centrioles; 3 — cell division spindle (mitotic spindle); 4 — aster (centrioles); 5 — nuclear envelope; 6 — kinetochore; 7 — polar fibres (microtubules); 8, 9 — chromosomes; 10 — centriolo-centromeric fibres (microtubules); 11 — the formation of the nucleus; 12 — cleavage furrow; 13 — midbody

condensed and partly extended state that gives them the collective appearance of chromatin granules instead of individual threads. Most extended regions of chromosomes represent sites where genetic instructions are being used for protein synthesis. *Chromatin* (*chromatin*) is a macromolecular complex composed mostly of DNA together with histones, gene-regulatory proteins, and a small, variable proportion of RNA.

Multinucleate cells are called a *syncytium* (*syncytium*).

**Tissue** (histos) is the phylogenetically developed integration (interaction) of cells and non-cellular structures. It specializes in performing of certain functions.

1. ***Epithelial tissue*** (*textus epithelialis*) develops from all three germ layers. This tissue is highly cellular, with little or no extracellular substance between cells. The epithelial tissue, or epithelium (plural = epithelia) provides the body's first line of protection from physical, chemical, and biological wear and tear. Many epithelial cells are capable of secretion and release mucous and specific chemical components onto their apical surfaces. Sloughing off of damaged or dead cells is a characteristic of a surface epithelium and allows airways and digestive tracts to rapidly replace damaged cells with new cells.

There are two types of this tissue; the *surface epithelium* (*epithelium superficiale*) forming the lining of the body, serous membranes, the inner coats of the tubular organs (Fig. 10), and the *glandular epithelium* (*epithelium glandulare*) which is presented by small and large glands (Fig. 11). The sur-

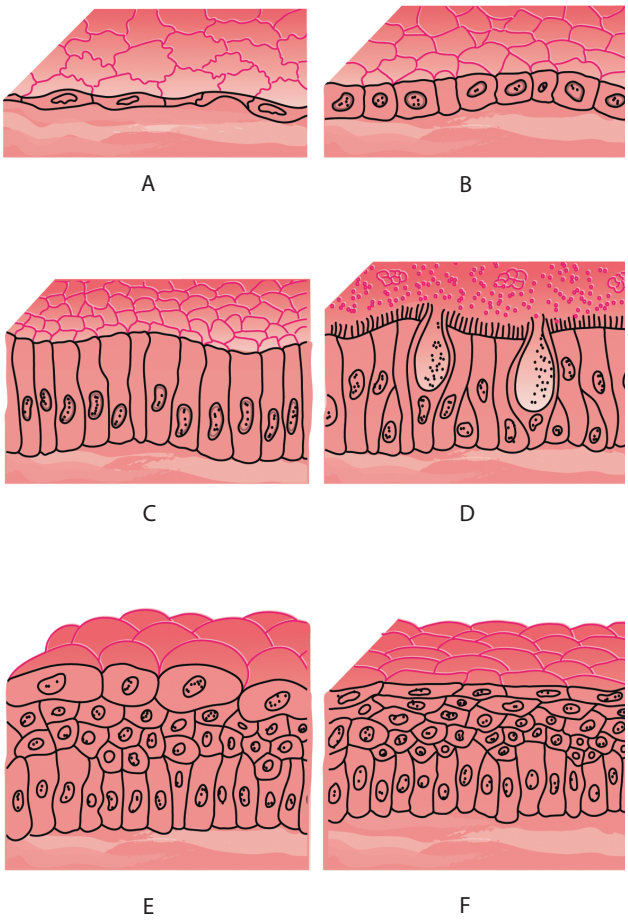


**Fig. 10.** Construction of epithelia [surface epithelia]: A — simple squamous epithelium (mesothelium); B — simple cuboidal epithelium; C — simple columnar epithelium; D — ciliated epithelium (pseudostratified columnar epithelium); E — transitional epithelium; F — non-keratinized stratified squamous epithelium



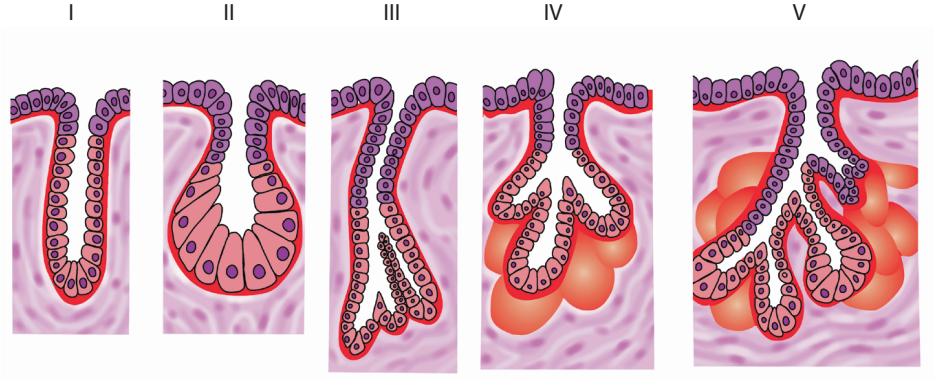


**Fig. 11.** Classification of multicellular glands: I — simple tubular gland; II — simple acinar gland; III — branched tubular gland; IV — branched acinar gland; V — compound tubulo-acinar gland

face epithelium is classified according to the shape of the cells and number of the cell layers formed. Cell shapes can be squamous (flattened and thin), cuboidal (boxy, as wide as it is tall), or columnar (rectangular, taller than it is wide). The number of cell layers in the tissue can be one if every cell rests on the basement membrane; it is the *simple epithelium* (*epithelium simplex*). Two and more layers of cells compose the *stratified epithelium* (*epithelium stratificatum*), and only the basal layer of cells is on the membrane. The *pseudostratified epithelium* (*epithelium pseudostratificatum*) (pseudo- means "false") consists of a single layer of irregularly shaped cells that give the appearance of more than one layer. Transitional kind of a specialized stratified epithelium contains cells the shape of which can be varied.

The *epithelial cells* (*cellulae epitheliales seu epitheliiocyti*) are typically characterized by the polarized distribution of organelles and membrane-bound proteins between their basal and apical surfaces. Adjoining cells constitute *intercellular junctions* (*junctiones intercellulares*) between their cell membranes. They are *simple* (*denticulate*, *digitiform*) or *complex junctions* (*desmosomes*, etc.). The *basement membrane* (*membrana basalis*) provides an attachment site for the epithelium and separates it from underlying connective tissue.



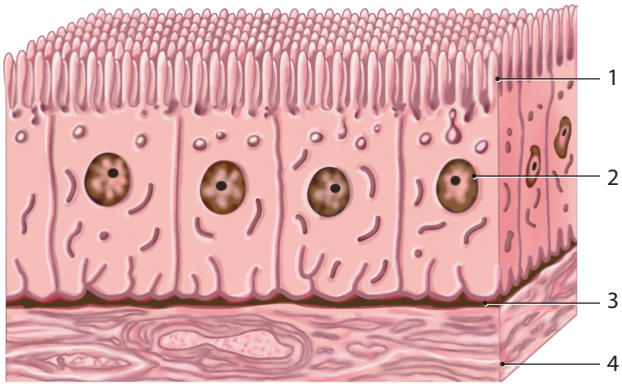


**Fig. 12.** The epithelial cells with cilia: 1 — microvilli; 2 — nucleus of the epitheliocyte; 3 — basal membrane; 4 — connective tissue proper

Epithelial cells can have got special structures: the microvilli, brush border, cilia, flagella, and tonofibrills.

The simple squamous epithelium includes the *mesothelium* (*mesothelium*) and *endothelium* (*endothelium*). It is present where rapid passage of chemical compounds is observed. The alveoli of lungs where gases diffuse, segments of kidney tubules, and the lining of capillaries are also made of it. The mesothelium forms the surface of the peritoneum, pleura, pericardium and internal organs. The simple cuboidal epithelium is in kidney tubules, ducts of the glands. The simple columnar epithelium covers the inner surface of the stomach, intestines, and female reproductive organs. Columnar cells of the epithelium have the cilia on their surface which are able to beat, so it is called ciliated epithelium (Fig. 12). It lines airways and uterine tubes. The *keratinized epithelium*, or *epidermis* (*epithelium stratificatum squamosum cornificatum* seu *epidermis*), covers the surface of the skin; the *non-keratinized epithelium* (*epithelium stratificatum squamosum non cornificatum*) lines the surface of the cornea, the inner surfaces of the oral cavity and esophagus. The *stratified cuboidal epithelium* and *stratified columnar epithelium* can be found in certain glands and ducts. The *transitional epithelium*, or *urothelium* (*epithelium transitionale* seu *urothelium*) is in the urinary system.

A gland is made up of one or more cells modified to synthesize and secrete chemical substances. Most glands consist of groups of epithelial cells. A gland can be classified as an *endocrine gland* (*glandula endocrina*), a ductless gland that releases secretions directly into surrounding tissues and fluids (endo- = "inside"), or an *exocrine gland* (*glandula exocrina*) whose secretions leave through a duct (exo- = "outside") that leads to the epithelial surface. Exocrine glands are classified as either unicellular or multicellular. The *unicellular exocrine glands* (*glandulae exocrinae unicellulares*) are composed by scattered single cells, such as a *goblet cell* (*epitheliocytus caliciformis*), found in the mucosa of the small and large intestine (Fig. 13). The duct of a multicellular exocrine gland is single in a *simple gland* (*glandula simplex*) but in *compound*

*glands* (*glandulae compositae*) it is divided into one or more branches.

2. ***Connective and supporting tissues*** (*textus connective atque sustinentes*) has a mesenchymal origin. These tissues typically have in common three characteristic components: *connective tissue cells* (*cellulae textuum connectivorum*), *extracellular matrix* (*matrix extracellularis*), and *fibres of connective tissues* (*fibrae textuum connectivorum*).

It is a multifunctional structure. It performs trophic (regulation of the cellular nutrition and participation in phagocytosis), mechanical (formation of organs' stroma, fascias, aponeuroses, cartilages, bones, creation the soft and bony skeletons of the body), reparative (participation in wound healing) functions.

There are several kinds of these tissues: the *connective tissue proper*, *mucoid or gelatinous connective tissue*, *reticular tissue*, *adipose tissue*, *cartilage tissue*, *bone or osseous tissue*.

The *connective tissue proper* (*textus connectivus proprius*; *textus conjunctivus*) includes the *loose* (*laxus*), *dense* (*compactus*) and *fusocellular* (*fusocellularis*) *connective tissues* (Figs. 14, 15).

The *cartilage tissue* (*textus cartilagineus*) (Fig. 16) is composed of *chondrocytes* (*chondrocyti*), *collagen and elastic fibres* (*fibrae collageni et fibrae elasticae*) in the *cartilage matrix* (*matrix cartilaginea*).

Three main kinds of cartilage tissue are *hyaline cartilage* (*cartilago hyalinea*), *fibrocartilage* (*cartilago fibrosa*), and *elastic cartilage* (*cartilago elastica*). Hyaline cartilage, the most common type of cartilage in the body, consists of short and dispersed collagen fibres and contains large amounts of proteoglycans. Both strong and flexible, it is found in the ribs and nose, covers articular surfaces of bones, and forms metaphyses. It makes up a template of the embryonic skeleton before bone formation. Fibrocartilage is tough because it has thick bundles of collagen fibres dispersed through its matrix. The knee and temporomandibular joints (discs and meniscus) and the intervertebral discs are composed of fibrocartilage. Elastic cartilage contains elastic fibers as well as collagen and proteoglycans. This tissue gives rigid support as well as elasticity. The external ear and cartilages of the larynx are constituted by elastic cartilage.

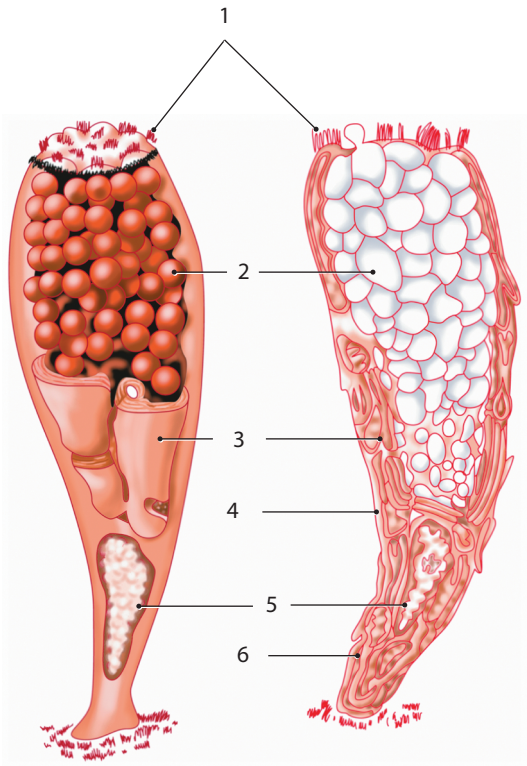


**Fig. 13.** The structure of a glandular cell — goblet exocrinocyte: 1 — microvilli; 2 — granules with mucous substance; 3 — Golgi apparatus; 4 — mitochondrion; 5 — nucleus; 6 — rough endoplasmic reticulum

The *bone tissue* (*textus osseus*) (Fig. 17) is a kind of connective tissue in which the *ground substance* (*substantia fundamentalis*) of the *bone matrix* (*matrix ossea*) contains collagen fibres and *hydroxyapatite cristalls* (*cristallum hydroxyapatiti*).

3. ***Haematolymphoid complex*** (*structurae haematolymphoideae*) consists of *blood cells* (*haemocyti*) and *plasma* (*plasma*). Blood cells are *red blood cells*, *erythrocytes* (*erythrocyti*), *white blood cells*, *leukocytes* (*leucocyti*) and *platelets*, *thrombocytes* (*thrombocyti*) (Fig. 18). The blood plasma, lymph plasma, chylomicron are kinds of plasma.

4. ***Muscle tissue*** (*textus muscularis*) is composed of the structures with contractile apparatus, and can change the length and shape of the organ. The different types of muscle tissue depend on their

**Fig. 14.** The loose connective tissue: 1 — macrophage; 2 — amorphous ground substance (extracellular matrix); 3 — plasma cell; 4 — adipocyte; 5 — blood vessel; 6 — monocyte; 7 — lymphatic capillary; 8 — eosinophilic granulocyte; 9 — fibrocyte; 10 — blood capillary; 11 — fibroblast; 12 — elastic fibre; 13 — lymphocyte; 14 — collagen fibres; 15 — reticular fibres; 16 — basophilic granulocyte

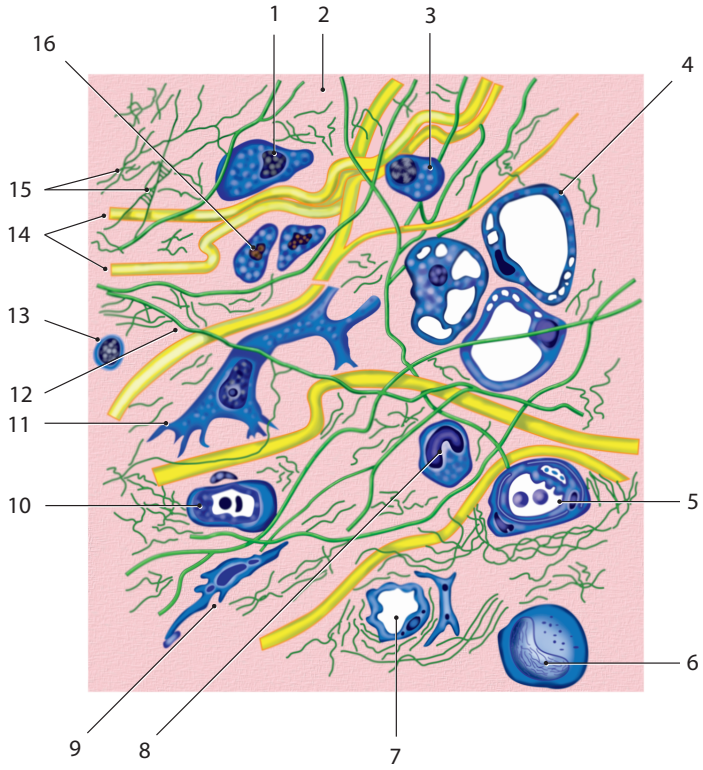




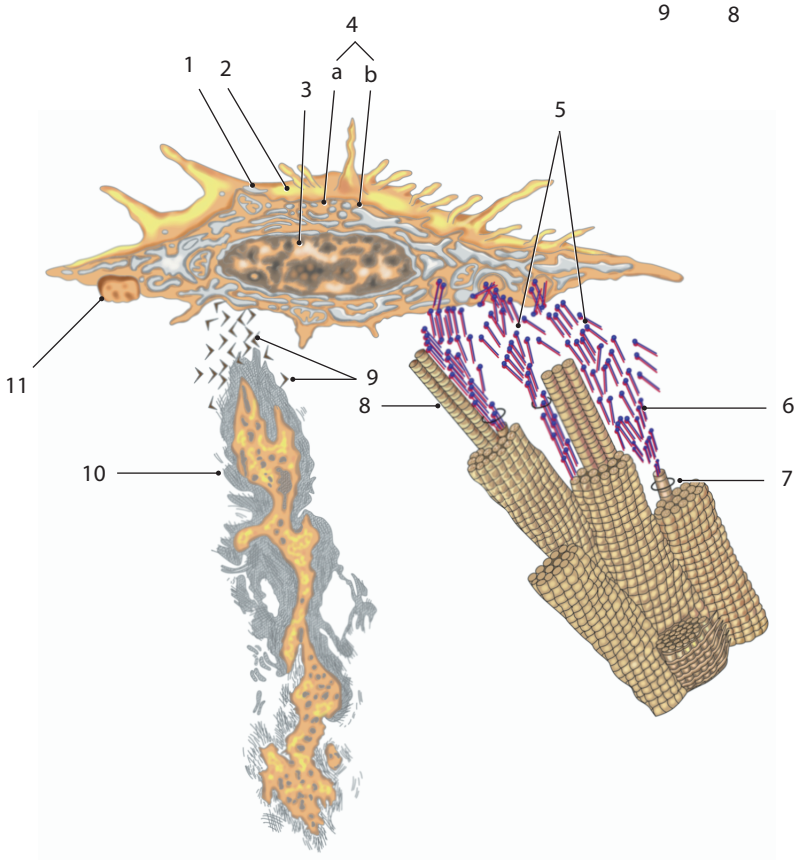


**Fig. 15.** The scheme of the fibroblast construction and the extracellular matrix: 1 — fibroblast; 2 — Golgi apparatus; 3 — nucleus; 4 — endoplasmic reticulum (a — smooth, b — rough); 5 — tropocollagen molecules that release from the cell; 6 — the process of polymerization of tropocollagen to the protofibrils; 7 — microfibrils; 8 — fibrils; 9 — elastin molecules; 10 — microfibrillar structural glycoprotein; 11 — elastic fiber into the fibroblast plasmalemma

**Fig. 16.** The cartilage tissue (hyaline cartilage): 1 — fibrous layer of perichondrium; 2 — chondrogenic layer of perichondrium; 3 — chondroblasts; 4 — chondrocytes in lacunae; 5 — interterritorial cartilage matrix (extracellular matrix); 6 — territorial cartilage matrix; 7 — isogenous aggregates

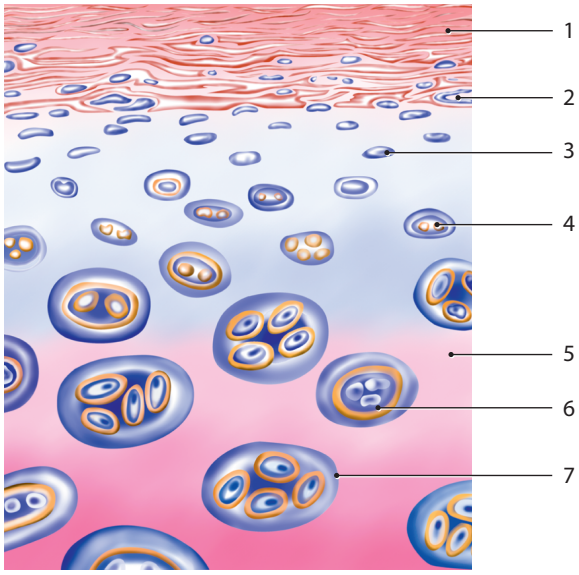




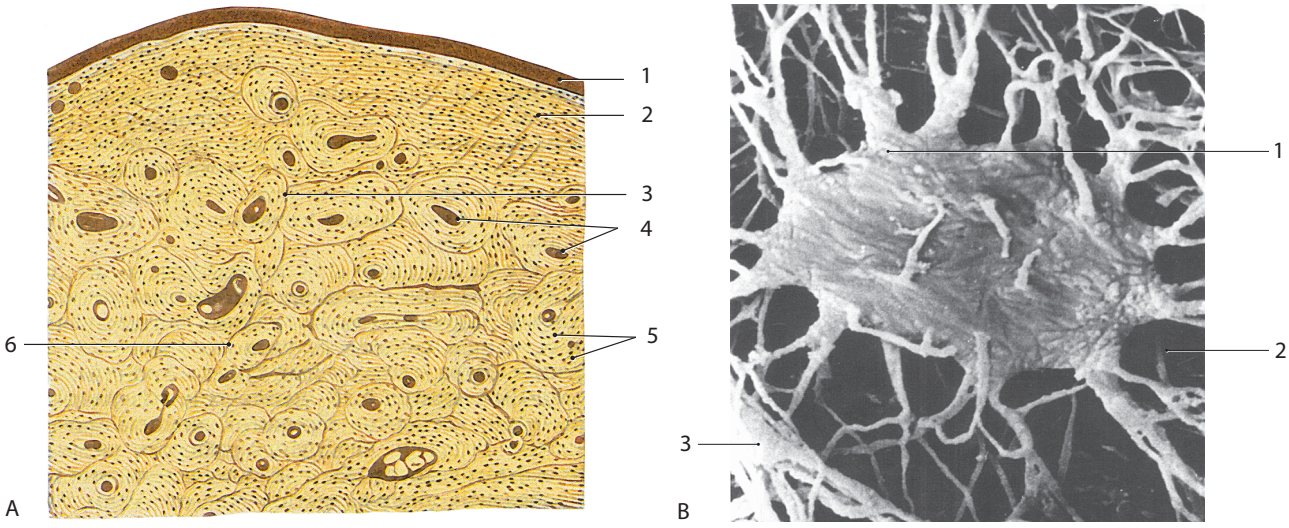


**Fig. 17.** The osseous tissue (A): 1 — periosteum; 2 — external circumferential lamellae; 3 — osteon concentric lamellae; 4 — central (osteonic) canals; 5 — osteocytes; 6 — interstitial lamellae. Osteocyte (B): 1 — osteocyte; 2 — osteocyte lacuna; 3 — wall of osteocyte lacuna

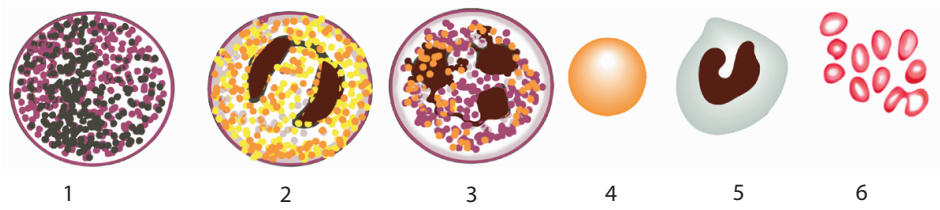


**Fig. 18.** The blood cells: 1 — basophilic granulocyte; 2 — eosinophilic granulocyte; 3 — segmented neutrophilic granulocyte; 4 — erythrocyte; 5 — monocyte; 6 — thrombocytes

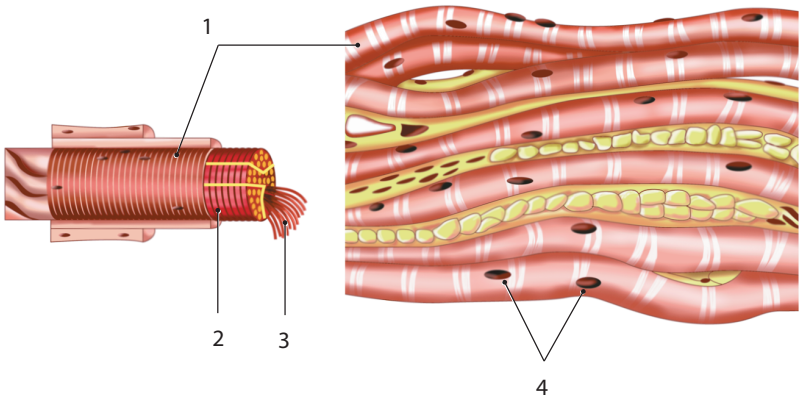


**Fig. 19.** The skeletal striated muscle: 1 — muscle fiber; 2 — sarcolemma; 3 — myofibrils; 4 — nuclei



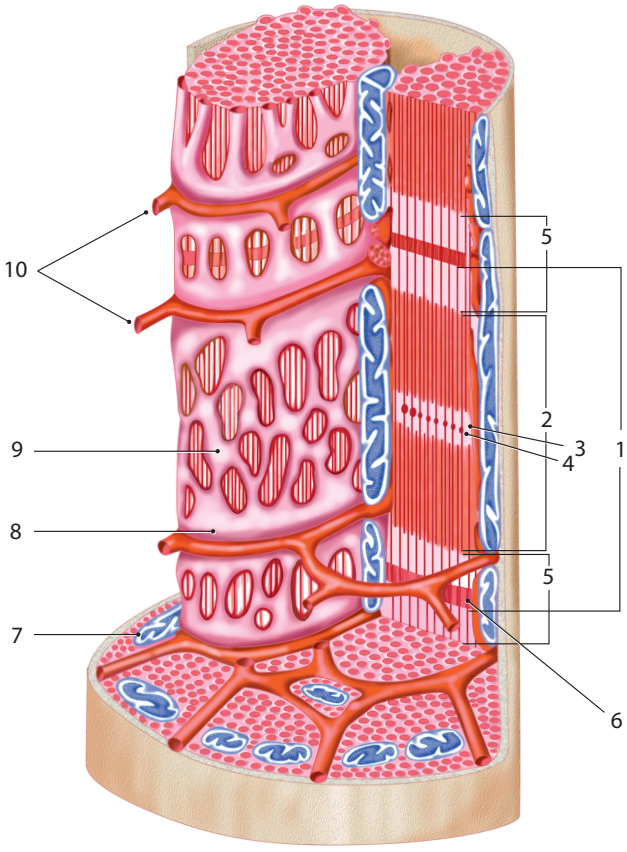


**Fig. 20.** Two myofibrils of muscle fibre (scheme): 1 — sarcomere; 2 — anisotropic band (A band); 3 — H band (pale zone); 4 — M line (mesophragma); 5 — isotropic band (I band); 6 — Z line, Z disc (telophragma); 7 — mitochondrion; 8 — terminal cistern; 9 — sarcoplasmic reticulum; 10 — transverse tubules, T tubules

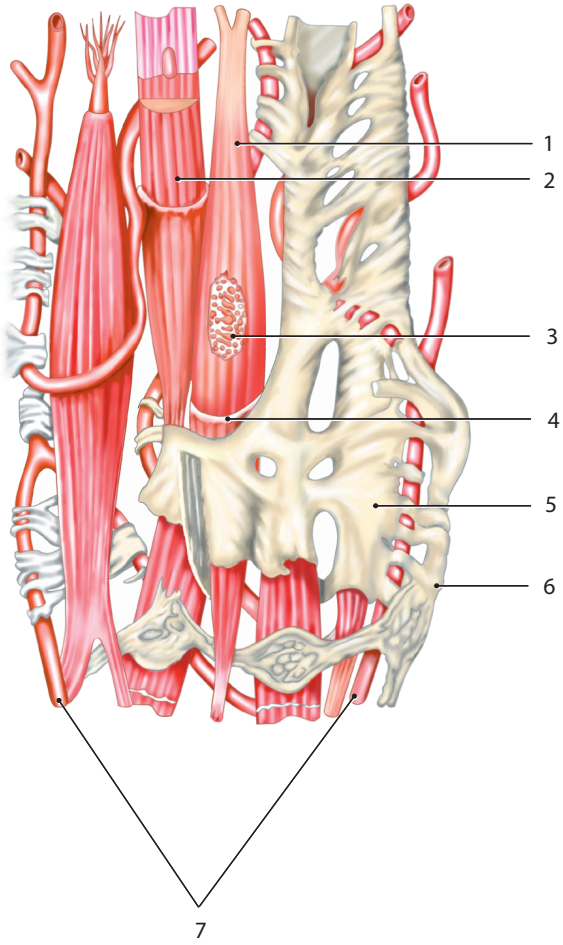


**Fig. 21.** The smooth muscle tissue (scheme): 1 — myocyte; 2 — myofibrils; 3 — nucleus; 4 — sarcolemma; 5 — endomysium; 6 — nerve; 7 — blood capillaries

origin. *Smooth tissue* (*textus muscularis nonstriatus* seu *textus muscularis levis*) develops from the mesenchyme. *Striated tissue* (*textus muscularis striatus*) derives from the segmented mesoderm or visceral mesoderm. Last is subdivided into the *skeletal striated muscle* (*textus muscularis striatus skeletalis*) and *visceral striated muscle* (*textus muscularis striatus visceralis*). The visceral muscle includes the *cardiac striated muscle* (*textus muscularis striatus cardiacus*) and *non-cardiac visceral striated muscle* (*textus muscularis striatus visceralis non cardiacus*).

Muscle tissue is formed by *muscle cells*, *myocytes* (*myocyti*) which are capable of contraction, and the support apparatus composed of collagen and elastic fibers connected groups of cells and organized a soft framework around them.

Myocytes differ in size, speed of the excitement and the contraction, periods of fatigue in the contracted state, also the areas of distribution. Smooth muscle tissue (Fig. 19) forms the media of arterial, venous and lymph vessels, ducts of glands, muscular layer of intestines, etc. It is innervated by the autonomous (vegetative) nervous system. Striated muscle tissue organizes skeletal muscles which are innervated by the somatic part of the nervous system (Figs. 20, 21). Striated cardiac muscle tissue forms the myocardium; it is innervated by the autonomic nervous system.

5. ***Nerve tissue*** (*textus nervosus*) has an ectodermal origin; it's composed of *neurons* (*neuroni*) and *neuroglia* (*neuroglia*) (Fig. 22). Glia surrounds the neurons, carrying out demarcation, supporting, trophic and protective functions. Neuroglia cells are varied in shape, size and relationship with neurons.

Each neuron has the *body* (*perikaryon*; *neurosoma*; *soma*; *corpus neuronis*), *axon* (*axon*), and *dendrite* (*dendritum*). Dendrites branch off the cell body and appear as thin extensions. A long process, the axon, protracts from the body and can be wrapped in myelin (Fig. 23) which is formed by *Schwann cell*, *neurolemmocyte* (*Schwannocytus*; *neurolemmocytus*). Processes of neurocytes with shells form the nerve fibers (neurofibrae). The totality of nerve fibers and connective tissue shells make a *nerve* (*nervus*).

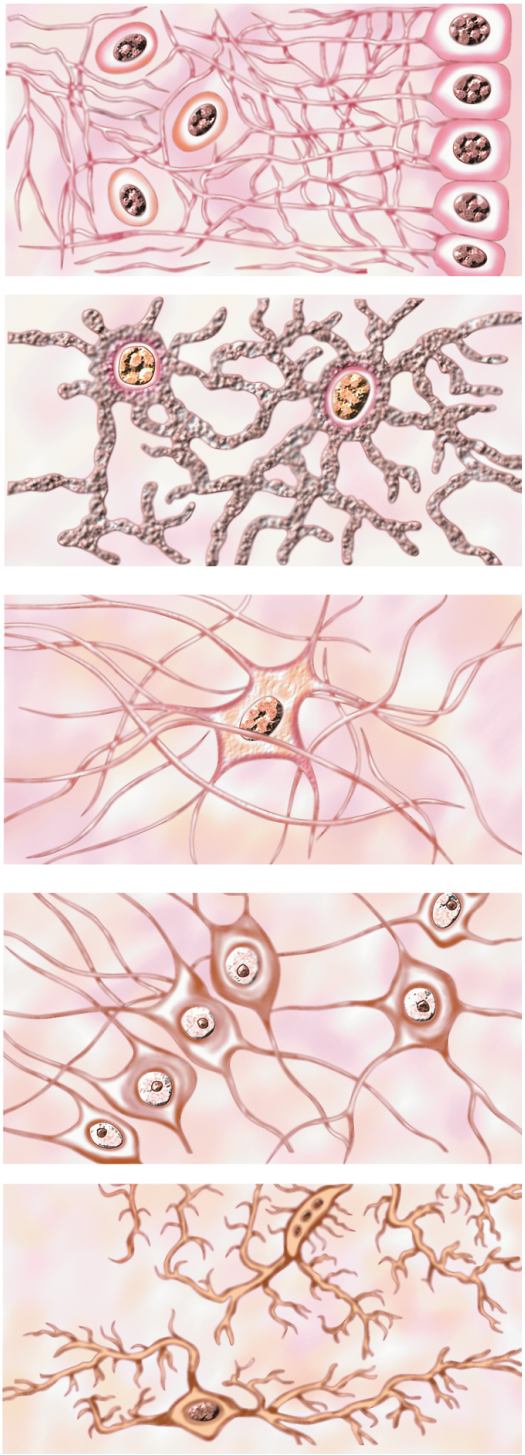


**Fig. 22.** The different types of central glial cells (scheme): 1 — ependymal cells; 2 — protoplasmic astrocytes; 3 — fibrous astrocytes; 4 — oligodendrocytes; 5 — microglial cells

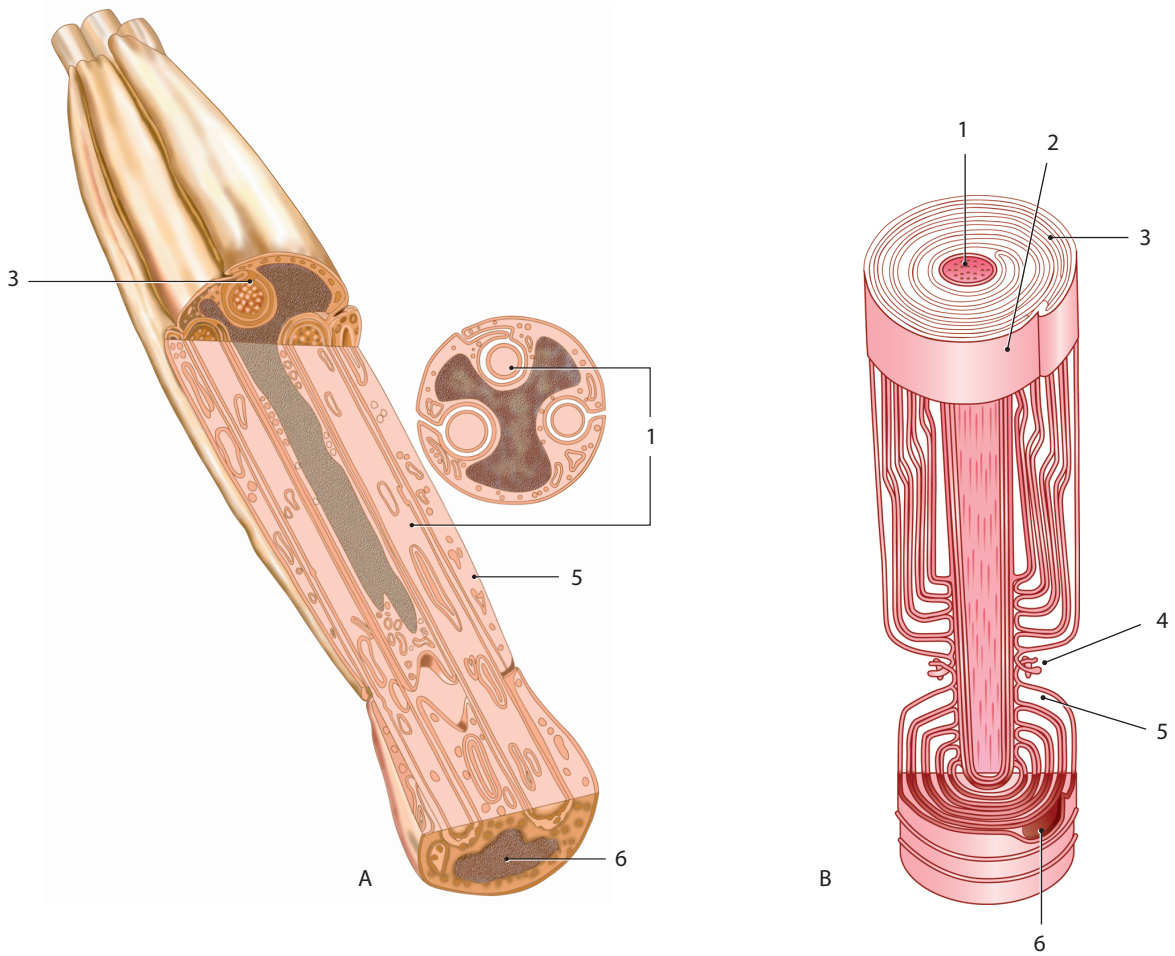


**Fig. 23.** The scheme of nonmyelinated (A) and myelinated (B) nerve fibers: 1 — axon; 2 — axolemma; 3 — mesaxon; 4 — myelin sheath gaps (node of Ranvier); 5 — cytoplasm of a neurolemmocyte (Schwann cell); 6 — nucleus of a neurolemmocyte

*Multipolar neurons* include several dendrites and a single axon; *unipolar neurons* have only a single process extending out from the nerve cell body. *Bipolar and pseudounipolar neurons* contain a single dendrite and axon (Fig. 24). According to functions neurons are divided into *motor*, *sensory*, *internuncial*, *secretory*, *pigmented* (Fig. 25). The *synapses* (*synapses*) are distinguished as *neuroneuronal*, *neuromuscular*, *neuroglial*, *neuroglandular*, *neurovascular*, *neurohaemal* (Figs. 26, 27).

**The organ** is the evolutionarily developed integration of tissues forming the compound organized coherent structure with a comparative autonomy. Organs in the anatomy are a part of the human body, a component of a particular system, which has its intrinsic shape, structure and position in the body, a characteristic architecture of the blood vessels and nerves, consisting of several types of tissues that performs a specific function or functions. We can consider any organ from this perspective (liver, heart, stomach, muscle, and so on). For example, the liver consists of different types of tissues, but the main one is epithelial, which provides clearance substances released to the liver from the gastrointestinal tract and bile formation.

There are a lot of individual organs in the human body. Every bone, muscle, large vessel, nerve, internal organ, etc. — is a separate organ. To find a complete classification is difficult because the organs are substantially different from each other in their position, shape, appearance and internal structure. The organs can be divided into the internal organs, the organs of support and movement, and the organs of integration, regulatory and sensory systems (sensory organs and skin). In turn, among the internal organs are tubal, parenchymal and specifically arranged organs.

All tubal organs have a common plan of structure and consist of three layers: the inner — mucosal layer, medium — muscle layer, and external — adventitia or serosa. Adventitia is presented by loose connective tissue. Serous membrane (peritoneum, pleura and pericardium) is also composed by connective tissue, the surface of which is lined with special epithelial cells — the mesothelium. Parenchymal organs are combined of stroma (connective tissue, forming their framework) and parenchyma (the main substance).

The system of support and movement includes such organs as the bones, ligaments and muscles. The teeth, consisting of hard tissues and the tongue, what is the mucous and muscular body are the specifically arranged organs. The organs of integrative, regulatory and sensory systems include brain and spinal cord, spinal and cranial nerves, sensory organs, skin, large vessels, the endocrine glands, etc.

Thus, the organ is a relatively separate anatomical structure, structural element, which creates a higher level of the organization — a system of organs.

**A system of organs** is the integration of the various organs which have a close anatomical connection with each other and perform a common function. The system of organs combines together organs with the same sources of development, similar structure and common functions. There are the following organ systems: skeletal system, system of connections, muscular system, alimentary system, respiratory system, urinary system, male/female reproductive systems, cardiovascular system, lymphoid system, nervous system.



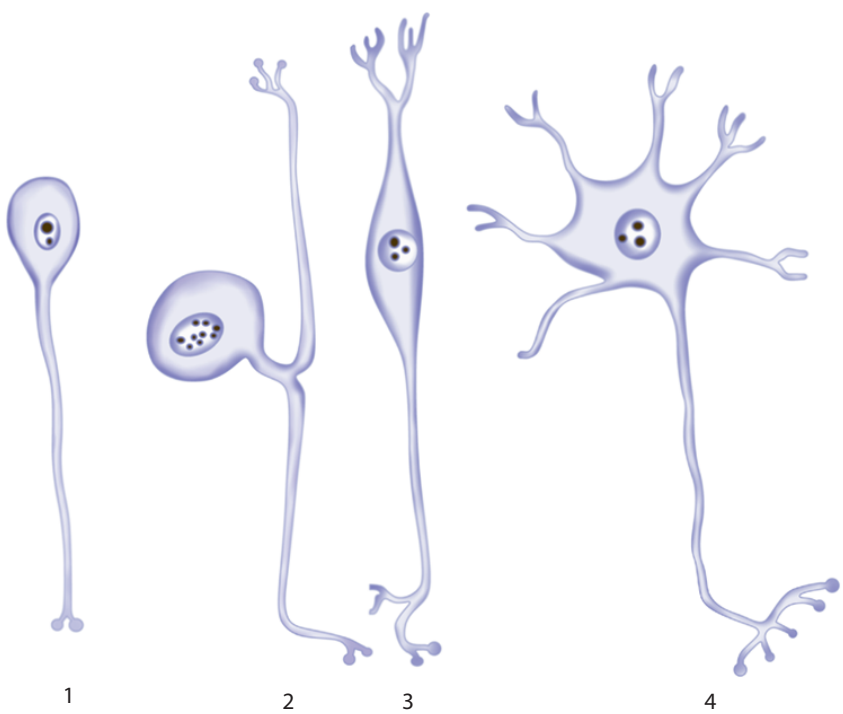


**Fig. 24.** The different neurons: 1 — unipolar; 2 — pseudounipolar; 3 — bipolar; 4 — multipolar

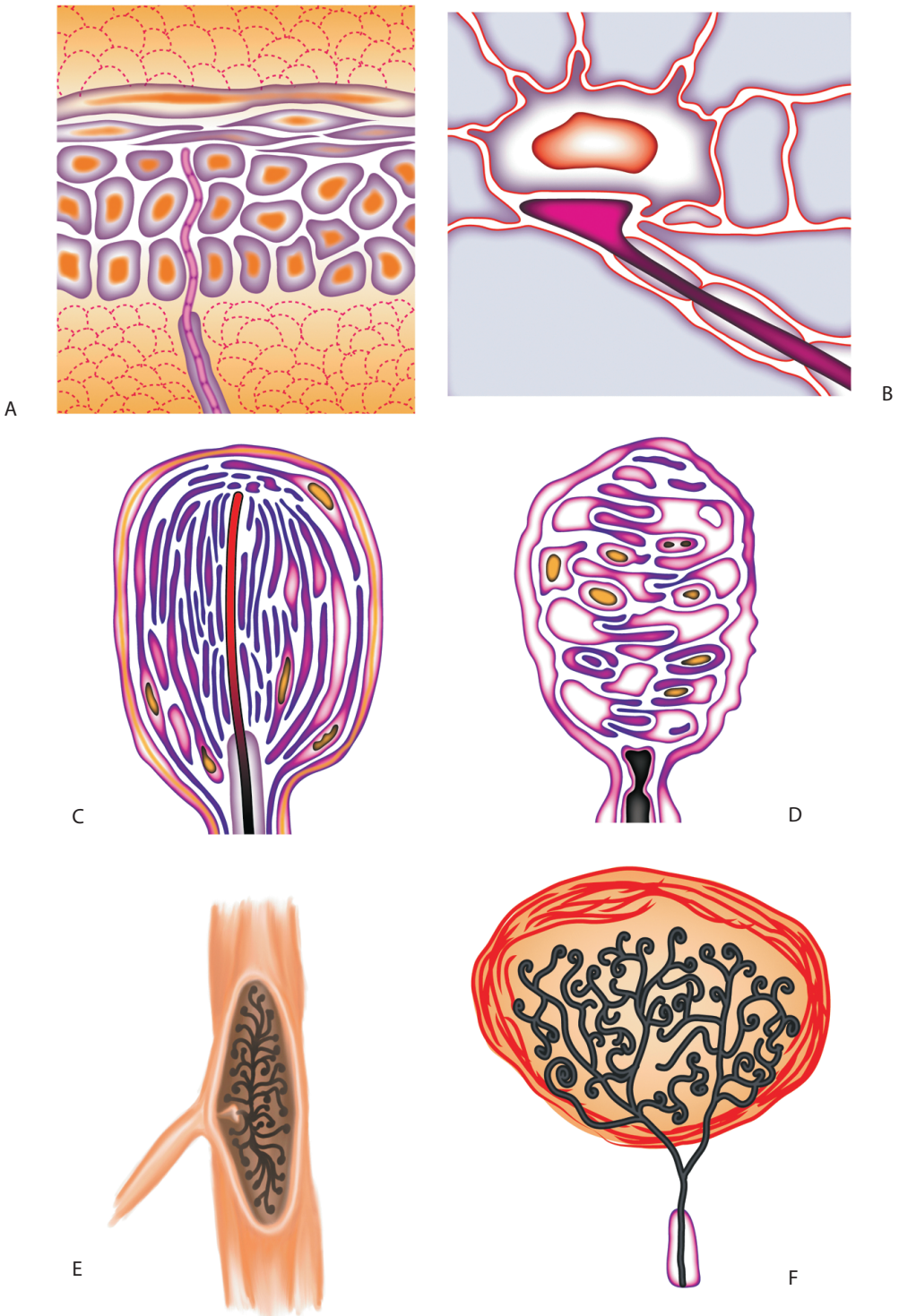


**Fig. 25.** The scheme of the sensory receptors: A — free nerve ending; B — Merkel tactile ending; C — Pacinian lamellar corpuscle; D — Meissner's tactile corpuscle; E — Ruffini ending (bulbous corpuscle); F — Krause's bulb

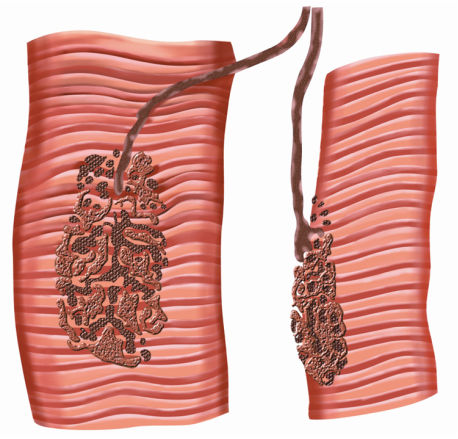

**Fig. 26.** The motor end plates

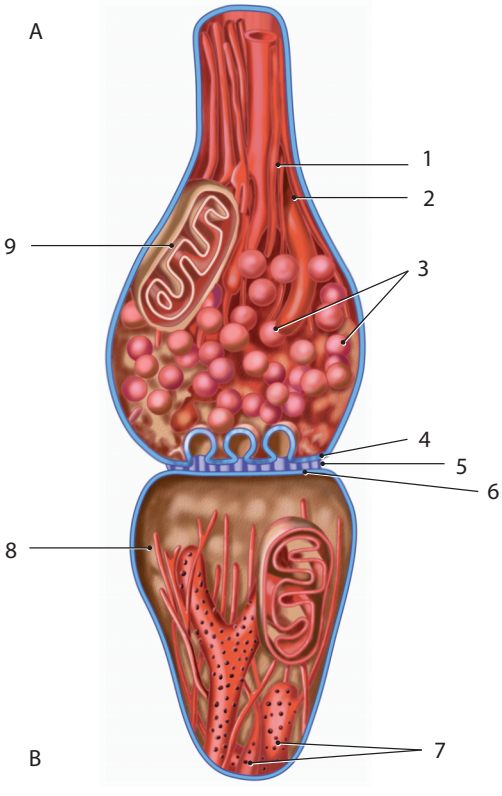


**Fig. 27.** The scheme of the neuroneuronal sinapse: A — presynaptic region; B — postsynaptic region; 1 — smooth endoplasmic reticulum; 2 — neurotubule; 3 — synaptic vesicles; 4 — presynaptic membrane; 5 — synaptic cleft; 6 — postsynaptic membrane; 7 — granular endoplasmic reticulum; 8 — neurofilaments; 9 — mitochondrion

The **apparatus** includes organs which have a different structure, but they are united by community of function (musculoskeletal and endocrine cell apparatus) or development (genitourinary apparatus).

The major organ systems can include subsystems. For example, components of the cardiovascular system are the heart, arterial, venous, lymphatic and microcirculatory systems.

The organs in the single system can be significantly differed by their structure. For example, the teeth, tongue, esophagus and liver as a parts of digestive system organs are completely different in their shape, position, color, texture, external and internal structure. First of all, the unity and integrity of the system are determined by the common thrust of the physiological processes.

However, most of organs inside one system have a single structure. Thus, pharynx, esophagus, stomach, small intestine and colon as part of the digestive system have the general principles of the structure wall. These include mucosa, muscle and outer (serous and adventitia) coats, although each of them are characterized by its typical features of the structure. These organs of the digestive system perform common functions — digestion and absorption of the formed substances.

So, the system of organs provides, first of all, the functional combining of organs. The organs of different systems may have a similar structure, such as hollow organs of the digestive and respiratory systems.

There are the main and auxiliary organs in every system. So, as part of the digestive system the small intestine and colon, liver, pancreas are major organs. Teeth, esophagus, stomach are auxiliary. The main organ of the system cannot be removed, it can only be transplanted. Moreover the system can perform its function without an auxiliary organ. It must be remembered that there are vital organs among the main organs. The termination of their function leads to death in a matter of minutes. Vital organs are the brain, heart, lungs, liver and kidneys.

**The human body as a whole** is the highest form of integration of systems. The great physiologist I.P. Pavlov pointed out that the human body is a living biological system, obeying the single laws for

all nature, the system is highly self-regulating, supporting itself, restoring, correcting and improving.

The human body as a living biological system exists only by continuous interaction with the environment. Biological properties characterize the human body as a living system. The main ones are:

- ✧ metabolism;
- ✧ irritability;
- ✧ ability to grow;
- ✧ ability to reproduce;
- ✧ mobility;
- ✧ stability (maintenance of a constant internal environment);
- ✧ plastic;
- ✧ integrity.

Thus, a holistic human body is a living biological system, with the ability to self-development, self-replication, self-regulation and has a high plasticity, mobility and sustainability.



## HUMAN POSITION IN NATURE

The human position in nature is determined by the evolutionary process, the development of living beings from lower to higher forms.

A human refers to the phylum Chordata, subphylum Vertebrata, class of Mammalia, Infraclass Eutheria, subclass Theria, order of Primates, Suborder Anthropoidea, Superfamily Hominoidea, families Hominidae, genus Homo, the Homo Sapiens species.

Homo sapiens is the specific name of modern man; the only extant species of the genus Homo. This species also includes extinct types of primitive man such as Cro-Magnon man, Java man, Heidelberg man, and Solo man.

## PARTS AND REGIONS OF HUMAN BODY

The human body is considered in the orthograde position (standing upright, with closed lower limbs, turned palms forward). There are the following *parts of the human body* (*partes corporis humani*): *head* (*caput*), *neck* (*collum*, *cervix*), *trunk* (*truncus*), *upper limb* (*membrum superius*), *lower limb* (*membrum inferius*), and *cavities* (*cavitates*). Each part of the body is divided into portions. The head includes the *forehead* (*sinciput*), *occiput* (*occiput*), *temple* (*tempora*), *ear* (auris) and *face* (*facies*); the neck contains the *anterior*, *lateral* and *posterior regions* (*regiones cervicales anterior*, *lateralis*, *posterior*); the trunk is composed of the *back* (*dorsum*), *thorax* (*thorax*), *abdomen* (*abdomen*), *pelvis* (*pelvis*); the upper limb consists of the *shoulder girdle* (*cingulum membri superioris*), *axilla* (*axilla*), *arm* (*brachium*), *elbow* (*cubitus*), *forearm* (*antebrachium*), *hand* (*manus*); the lower limb is collected by the *pelvic girdle* (*cingulum membri inferioris*), *bottocks* (*nates*, *clunes*); *thigh* (*femur*), *knee* (*genu*), *leg* (*crus*), *foot* (*pes*).

The human body is divided into *regions* (*regiones corporis*) which are separated by borders, carrying out by the clearly visible external points for convenience of description of layered anatomy and the possibility of the location of pathological processes (Figs. 28, 29).

## CONSTITUTION

**Constitution** (lat. *habitus* — appearance) is a morphological concept including an assessment of structural features, shape, dimensions and proportions of parts of the human body. There are three basic forms of the body (Fig. 30).

The mesomorphic (normosthenic) type is characterized by average height, well-developed skeleton and muscles, optimal proportions of the trunk, limbs and head, a weak deposition of subcutaneous fat. This is the most common shape of the body (75–80%).

The man of dolichomorphic (asthenic) type of constitution is tall with less developed musculature and skeleton, less fat tissue.

The brachymorphic (hypersthenic) type man is small or middle, has a short neck and large head sizes, short limbs, a broad chest and a tendency to deposit fat.

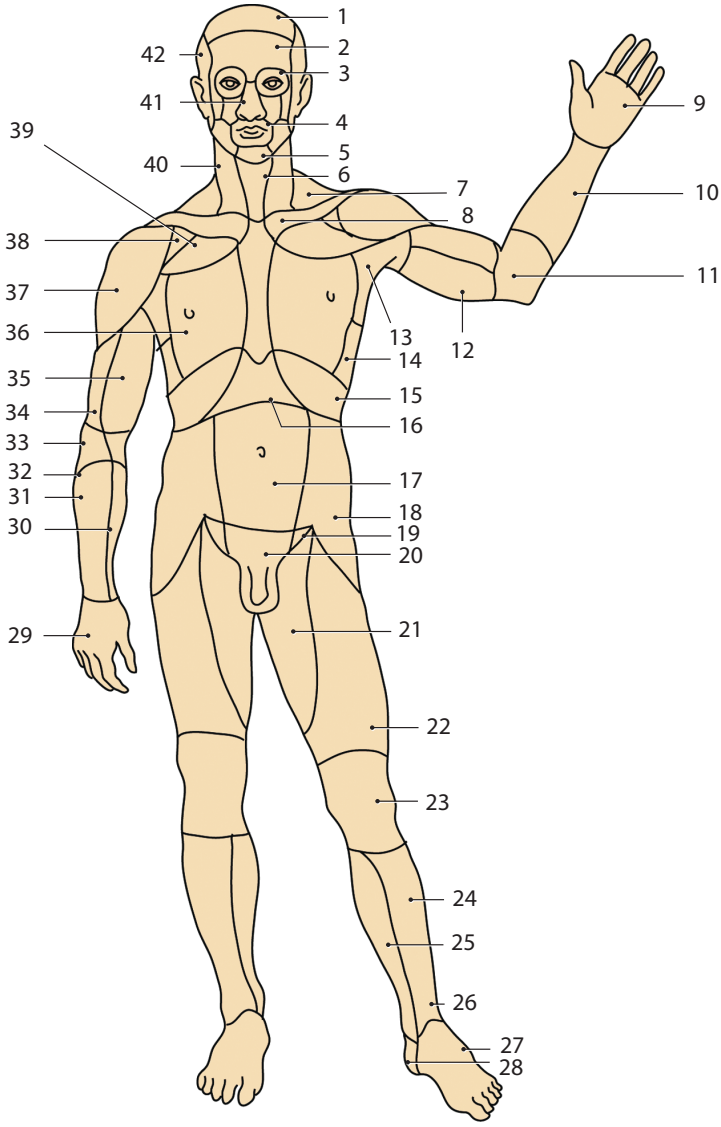


**Fig. 28.** The regions of a human body (anterior view): 1 — parietal region; 2 — frontal region; 3 — ocular region; 4 — oral region; 5 — mental region; 6 — anterior cervical region; 7 — lateral cervical region; 8 — clavicular region; 9 — palmar region; 10 — anterior region of the forearm; 11 — anterior region of the elbow; 12 — posterior region of the arm; 13 — axillary region; 14 — lateral pectoral region; 15 — hypochondriac region; 16 — epigastric region; 17 — umbilical region; 18 — lateral abdominal region (flank); 19 — inguinal region (groin); 20 — pubic region; 21 — medial aspect of the thigh; 22 — anterior region of the thigh; 23 — anterior region of the knee; 24 — anterior region of the leg; 25 — posterior region of the leg; 26 — anterior talocrural region; 27 — dorsum of the foot; 28 — heel region; 29 — dorsum of the hand; 30 — anterior region of the forearm; 31 — forearm; 32 — posterior region of the forearm; 33 — posterior region of elbow; 34 — posterior region of the arm; 35 — anterior region of the arm; 36 — mammary region; 37 — deltoid region; 38 — clavipectoral triangle; 39 — infraclavicular fossa; 40 — sternocleidomastoid region; 41 — nasal region; 42 — temporal region

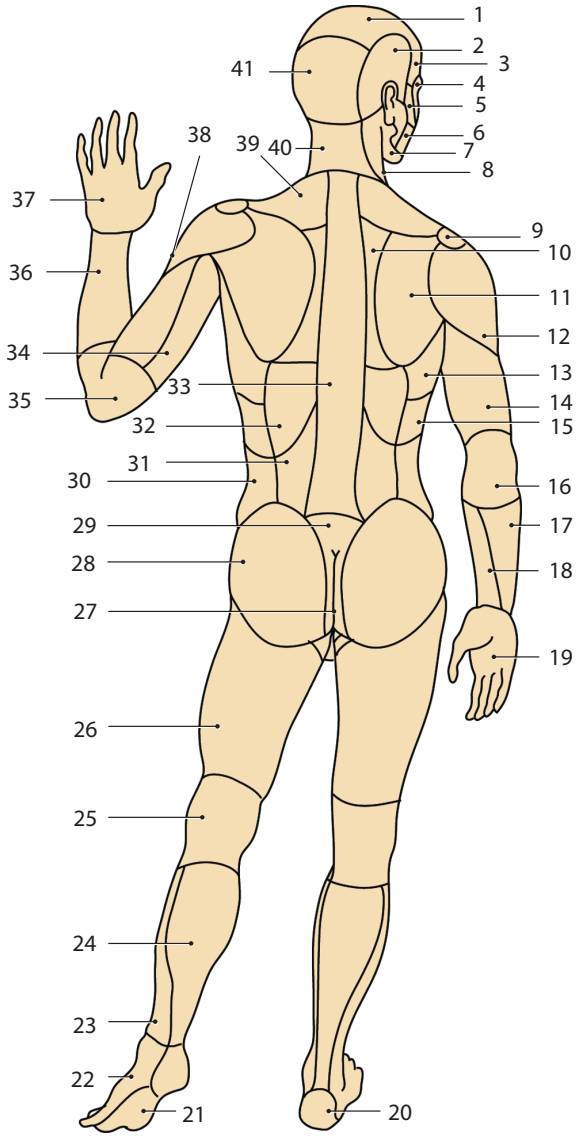


**Fig. 29.** The regions of a human body (posterior view): 1 — parietal region; 2 — temporal region; 3 — frontal region; 4 — orbital region; 5 — zygomatic region; 6 — buccal region; 7 — submandibular triangle; 8 — sternocleidomastoid region; 9 — acromial region; 10 — interscapular region; 11 — scapular region; 12 — deltoid region; 13 — lateral pectoral region; 14 — posterior region of the arm; 15 — infracostal region; 16 — posterior region of the elbow; 17 — posterior region of forearm; 18 — anterior region of the forearm; 19 — palm; 20 — heel region; 21 — sole (plantar region); 22 — dorsum of foot; 23 — anterior region of the leg; 24 — posterior region of the leg; 25 — posterior region of the knee; 26 — posterior region of the thigh; 27 — anal triangle; 28 — gluteal region; 29 — sacral region; 30 — lateral abdominal region (flank); 31 — lumbar region; 32 — infrascapular region; 33 — vertebral region; 34 — posterior region of the arm; 35 — posterior region of the elbow; 36 — posterior region of the forearm; 37 — dorsum of the hand; 38 — anterior region of the arm; 39 — suprascapular; 40 — posterior cervical region; 41 — occipital region

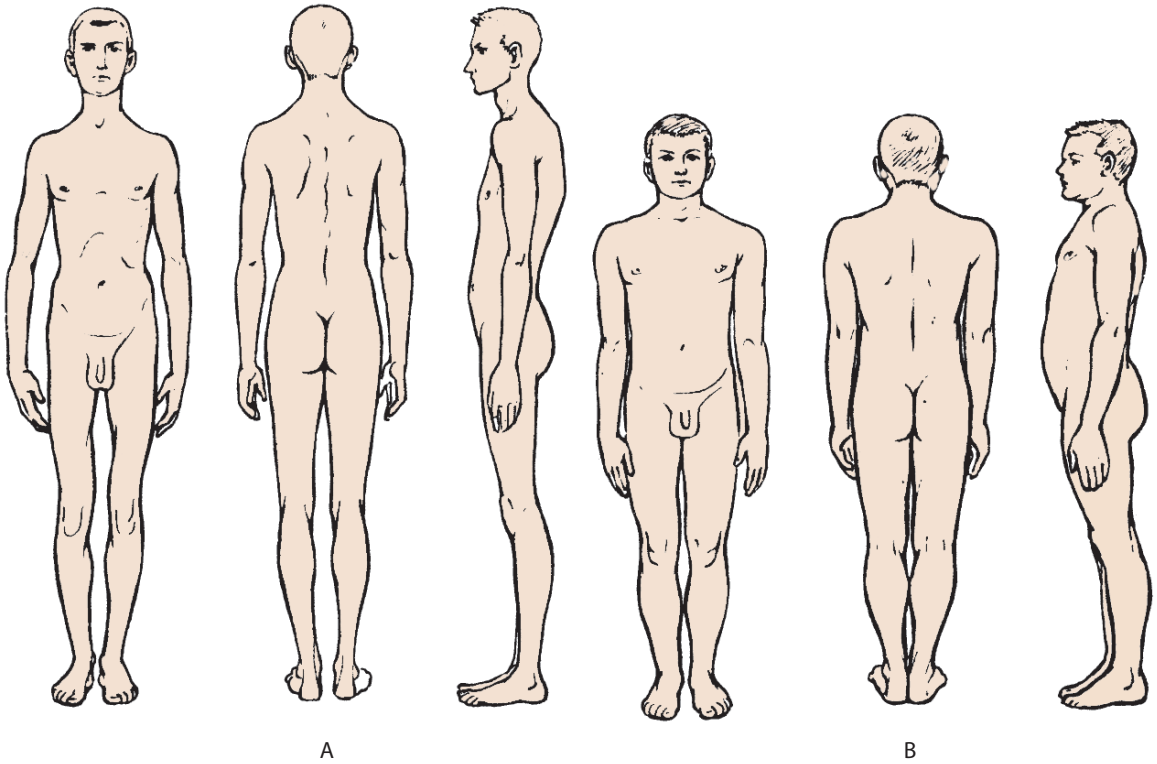


**Fig. 30.** The types of human body constitution: A — dolichomorphic type; B — brachymorphic type



Most people have a mixed form of the body which occupies an intermediate position between these options. There are the following criteria to determine the shape of the adult body.

The ratio of the vertical size of the body to the cross sizes means the ratio of the height to the width of the shoulders. This ratio is more than 4,4 for the dolichomorphic type of the body; it is less than 3,5 for the brachymorphic type; and it is 3,5–4,4 for the mesomorphic type.

The infrasternal (epigastric) angle at patients with dolichomorphic physique is acute; people with brachymorphic type have obtuse angle; and the mesomorphic patients have the angle which is approximately 90°.

Pine's index is an integral value obtained as the length (cm) minus the chest circumference (cm) minus weight (kg).

For dolichomorphic persons Pine physique index is 30–50; for brachymorphic patients it is less than 10; for mesomorphic people it is 10–30.

A constitution is associated not only with the differences in the structure of the organs (bones, muscles, subcutaneous fat), which are available for external examination and palpation, but it also causes a different position, shape and dimensions of the internal organs. So, the dolichomorphic body (asthenic type), in addition to the previously mentioned external signs, has the long limbs and neck, flat chest, acute epigastric angle (less than 90°), the scapulae usually prominented from the chest, moderately developed muscles, small sizes of parenchymal organs: the heart — "hanging" (because of the low position of the diaphragm), the ptosis (descending) of the kidneys, liver, stomach.

The mesomorphic physique (a normosthenic type) is characterized by the average facial features, the proportional ratio of body sizes in the length and width, and straight epigastric angle (approximately 90°).

Brachymorphic figure (a hypersthenic type) is characterized by a tendency to deposit fat, epigas-

tric angle is more than 90°, intercostal spaces are narrow, ribs are wide, the scapulae fit snugly to the chest, the diaphragm is high, the stomach is located upper and horizontally, the intestine is long.

A sexual dimorphism is typical for body proportions. The sex differences in bodies are associated with the development of the skeleton, muscles, and subcutaneous fat. The male body has large sizes, narrow pelvis and wide shoulder girdle. A woman's body is shorter, has a wider pelvis and narrow shoulder girdle. At the same body length ratio of the length of arms and legs is more in men, they have bigger shoulder width, and women have the bigger width of the pelvis.

Also, there are racial and ethnic morphological features. There are three races: Caucasoid (white), Mongoloid (yellow) and Negroid-Australoid (black). Each of them is characterized by a certain color of skin and hair, the eye slits and shape of the eyelids, face, length of the body, fatness and proportions of the body.



## ANATOMICAL TERMINOLOGY

Anatomical terminology contains the concepts which are used in anatomy, and is divided into **general anatomical terminology** reflecting the common features of organs, **special (systemic)** terminology included names of specific anatomical structures, and **service** terminology. There are international (Latin) and national anatomical terminologies (Russian, German, English, etc.).

A list of names adopted in each science constitutes a **nomenclature**. The first anatomical nomenclature in Latin language was adopted in Basel (1895), so it was called Basel (BNA). In Paris (1955) the single standard international anatomical nomenclature was approved, it's known as the Paris (PNA). Nomenclature exposed to revision and additions with the development of the anatomical science. This publication is provided in compliance with the International anatomical terminology (1998, 2003).

When topography of organs, vessels and nerves is considered we use conventional plane and axis, as well as terms that indicate the location and direction of the body. There are three planes: horizontal, frontal and sagittal (Fig. 31).

The *horizontal plane* (*plana horizontalia*) divides the body into upper and lower parts. The *frontal*, or *coronal plane* (*plana frontalia*; *plana coronalia*) corresponds to the plane of the forehead (from Latin.

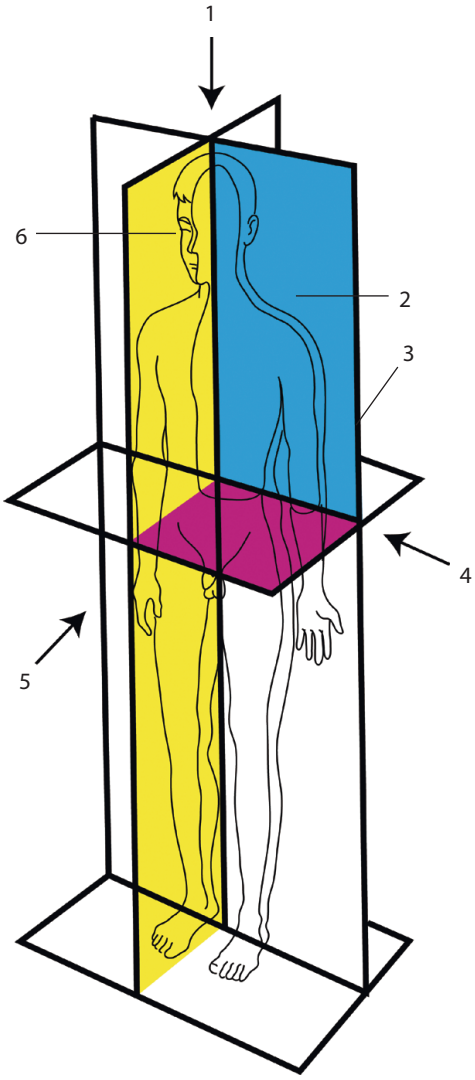


**Fig. 31.** The axes and planes. The scheme (anterior view): 1 — vertical (longitudinal) axis; 2 — frontal (coronal) plane; 3 — horizontal plane; 4 — transverse axis; 5 — sagittal axis; 6 — sagittal plane

*frons* — forehead), it passes through the body vertically, for example through both hip joints. It divides the body into anterior and posterior portions. The *sagittal plane* (*plana sagittalia*) is located vertically too, but from the front to the back. If the sagittal plane passes through the middle of the body, it is called the median plane. The median plane divides the body into left and right sides. There are three axes, the vertical axis runs from the top to the bottom, the sagittal axis is from the front to the back and the frontal, or transverse, axis is situated from the left side to the right side. All anatomical descriptions assume that the body is in the conventional 'anatomical position', i.e., standing erect and facing forwards, upper limbs by the side with the palms facing forwards, and lower limbs together with the toes facing forwards.

**QUESTIONS FOR SELF-CONTROL**

1. What is a cell?
2. What are the main roles of cell organelles?
3. List the types of tissues and their basic functions.
4. What types of epithelial tissues do you know? Give a brief description of each tissue.
5. What are the differences between the smooth muscle and striated muscle tissues?
6. Give the definition of the organ, system of organs and the human body as a whole.
7. List the individual constitutions of people in the same sex and age. Describe each kind of the constitution of the body.