

TOPOGRAPHIC ANATOMY AND OPERATIVE SURGERY

WORKBOOK

Edited by
Professor S.S. Dydykin

In 2
parts

Part II

Ministry of Science and Higher Education of the Russian Federation

Recommended by the Coordination Council for the field of education
«Healthcare and Medical Sciences» as a workbook for use in education
that implement basic professional educational programs of higher
education in the areas of specialty training 31.05.01 «General Medicine»,
31.05.02 «Pediatrics»

Registration number of the review 036 dated December 19, 2019

Course _____ Group _____ Faculty _____

(Full name of student)

(Full name of teacher)



Moscow
«GEOTAR-Media»
PUBLISHING GROUP
2022

CONTENTS

13. TOPOGRAPHIC ANATOMY OF THE ANTEROLATERAL ABDOMINAL WALL	8
14. TOPOGRAPHIC ANATOMY AND OPERATIVE SURGERY OF FEMORAL HERNIA AND HERNIAS OF THE ANTEROLATERAL ABDOMEN WALL	13
15. TOPOGRAPHICAL ANATOMY OF THE SUPERIOR COMPARTMENT OF THE ABDOMINAL CAVITY	26
16. TOPOGRAPHICAL ANATOMY OF THE INFERIOR COMPARTMENT OF THE ABDOMINAL CAVITY	36
17. OPERATIONS ON THE STOMACH, LIVER, GALLBLADDER, SPLEEN AND PANCREAS	42
18. INTESTINAL SUTURES	53
19. SURGERY OF THE SMALL AND LARGE INTESTINE	57
20. TOPOGRAPHICAL ANATOMY AND OPERATIVE SURGERY OF THE LUMBAR REGION AND RETROPERITONEAL SPACE	63
21. TOPOGRAPHIC ANATOMY OF LESSER PELVIS AND PERINEUM	73
22. OPERATIVE SURGERY OF PELVIS AND PERINEUM	86
23. TOPOGRAPHIC ANATOMY AND OPERATIVE SURGERY OF THE CHEST	97
24. TOPOGRAPHIC ANATOMY AND OPERATIVE SURGERY OF MEDIASTINUM	110

13. TOPOGRAPHIC ANATOMY OF THE ANTEROLATERAL ABDOMINAL WALL

Topics of the lesson: Surface limits and landmarks of the anterolateral abdominal wall, regions of the abdomen. Projections of the peritoneal and retroperitoneal organs on the anterolateral abdominal wall. Structure of the anterolateral abdominal wall in the medial and lateral regions, blood supply, innervation, venous and lymphatic drainage, portocaval and cava-caval anastomoses, their practical meaning. Weak places, structure of the white abdominal line, umbilical ring, semilunar line. Inguinal region, inguinal triangle, inguinal canal and its content in men and women, inguinal space and its practical meaning. Structure of the spermatic cord. Topographic anatomy of the internal surface of the anterolateral abdominal wall, folds and recesses of the parietal peritoneum, their practical meaning. Congenital defects of the anterolateral abdominal wall: umbilical fistula, umbilical canal hernia (omphalocele).

13.1. Sign the names of the landmarks in the Fig. 13.1, draw the surface limits of the anterolateral abdominal wall.

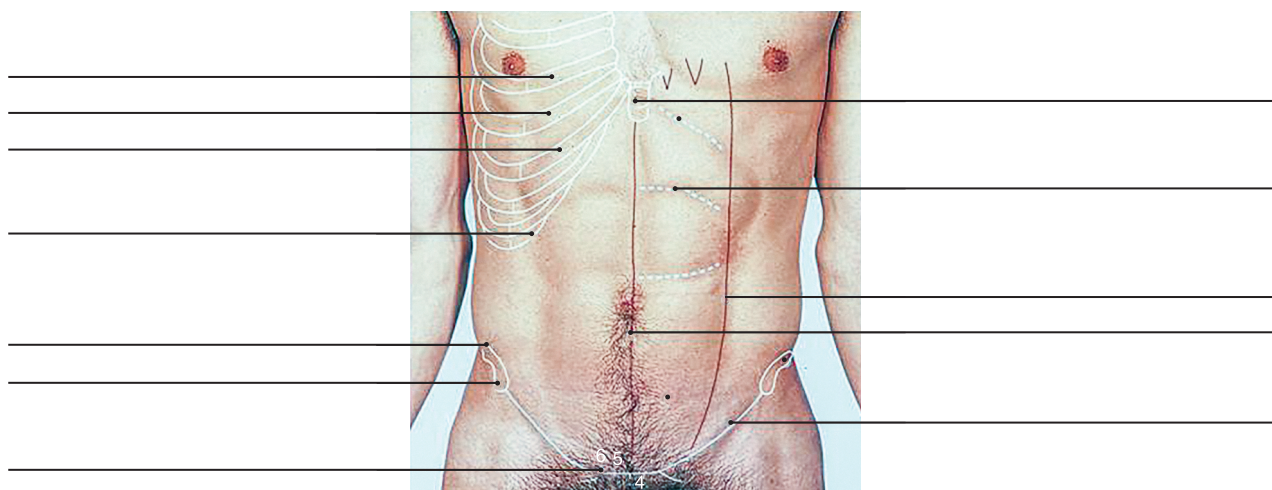


Fig. 13.1. Surface landmarks of the anterolateral abdominal wall

13.2. In the Fig. 13.2, draw the limits of the 9 regions of the anterolateral abdominal wall and sign their English and Latin names. Complete the table about holotopy of the abdominal organs.

Region 1 — <i>Regio hypochondrica dextra</i>	Region 2 —	Region 3 —
Organs: <i>The right lobe of the liver</i> — — — — — —	Organs: — — — — — —	Organs: — — — — — —
Region 4 —	Region 5 —	Region 6 — <i>Regio abdominalis lateralis sinistra</i>



Organs: — — — — — —	Organs: — — — — — —	Organs: — — — — — —
Region 7 —	Region 8 —	Region 9 —
Organs: — — — — — —	Organs: — — — — — —	Organs: — — — — — —

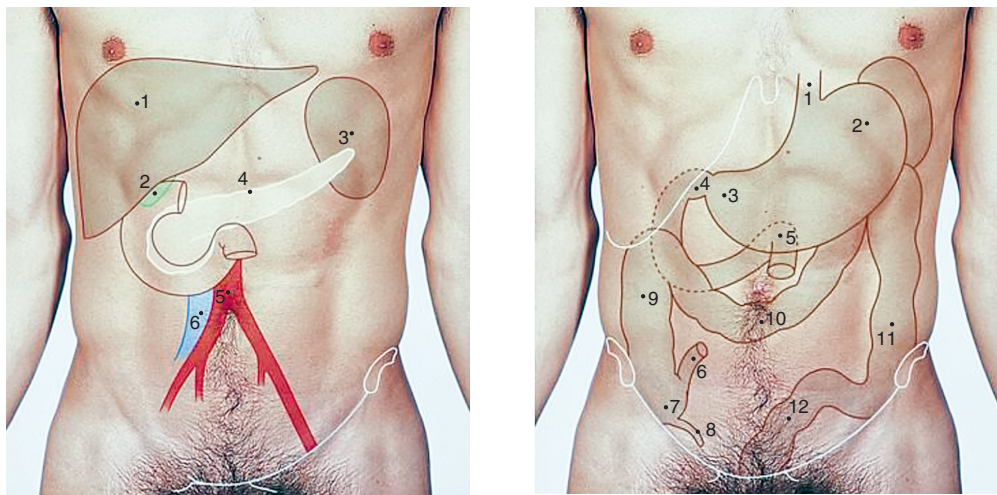


Fig. 13.2. Regions of the anterolateral abdominal wall and holotopy of the abdominal organs.

13.3. Sign the English and Latin names of the muscles that are indicated on the Fig. 13.3.

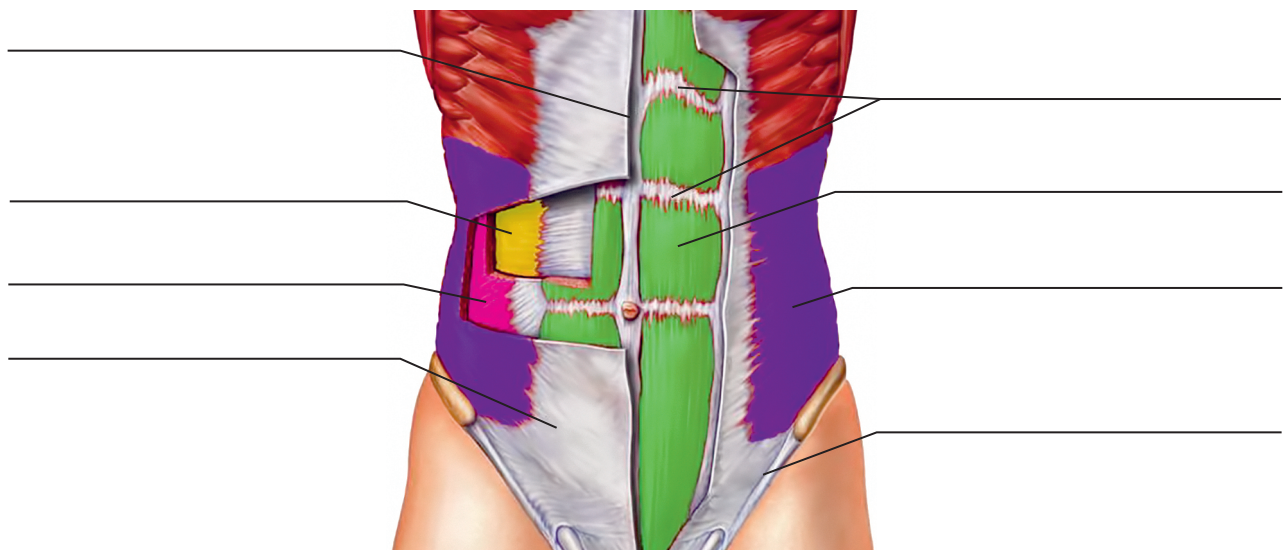


Fig. 13.3. Muscles of the anterolateral abdominal wall

13.4. Sign the English and Latin names of the layers that construct the rectus sheath above and below the umbilicus using the Fig. 13.4. Choose the image that illustrates structure of the rectus sheath above umbilicus and the image that illustrates structure of the rectus sheath below the umbilicus.

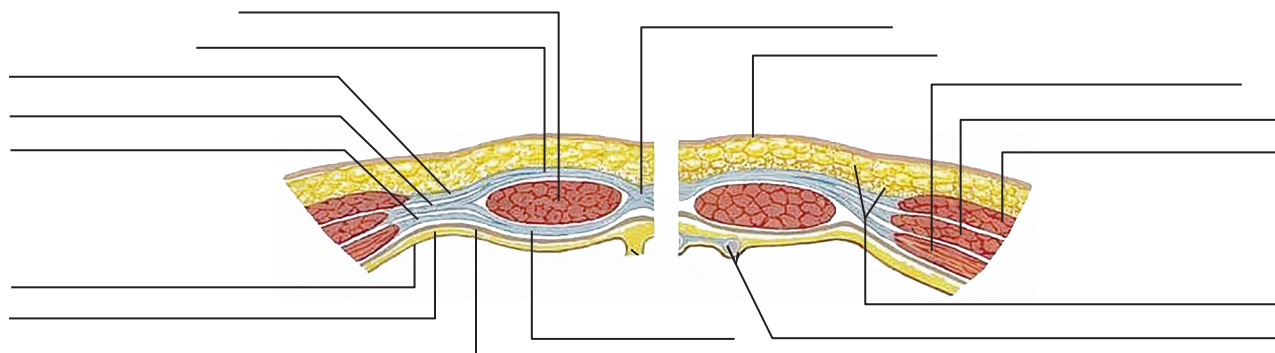


Fig. 13.4. Cross section of the anterolateral abdominal wall

A. _____ B. _____

13.5. Sign the English and Latin names of the arteries that supply the anterolateral abdominal wall using the Fig. 13.5. Write the names of the major arteries:

- 1) _____
- 2) _____
- 3) _____

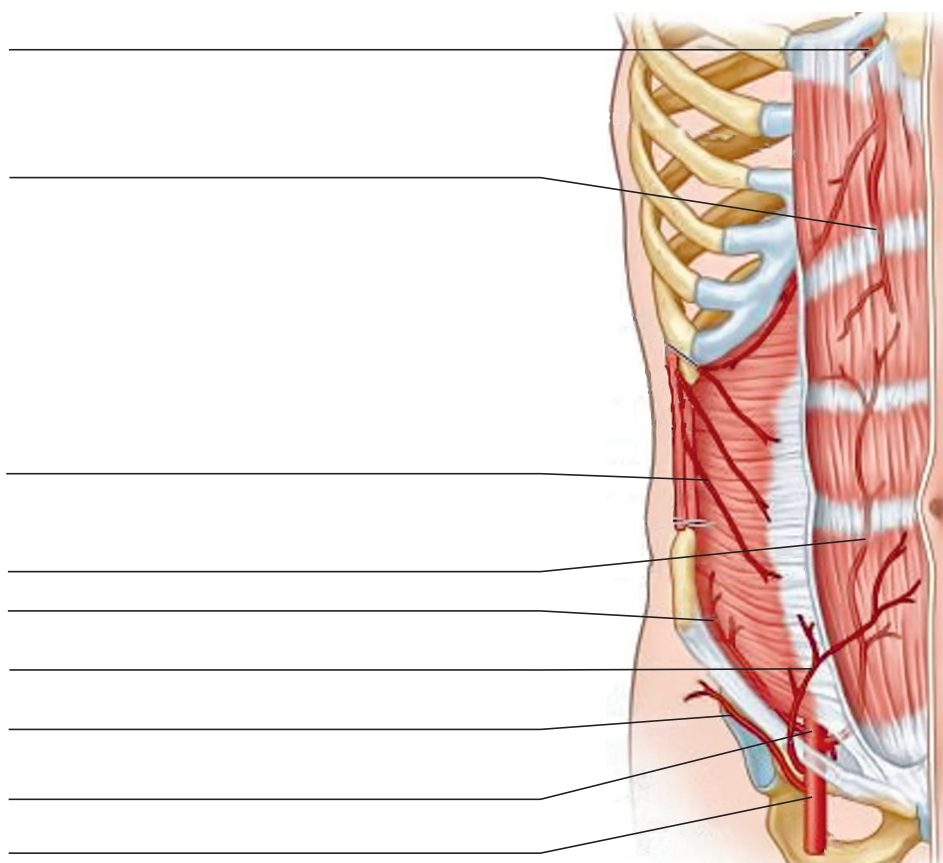


Fig. 13.5. Arterial supply to anterolateral abdominal wall

13.6. Sign the English and Latin names of the anatomic structures of the internal surface of the anterolateral abdominal wall using the Fig. 13.6. Answer the questions.

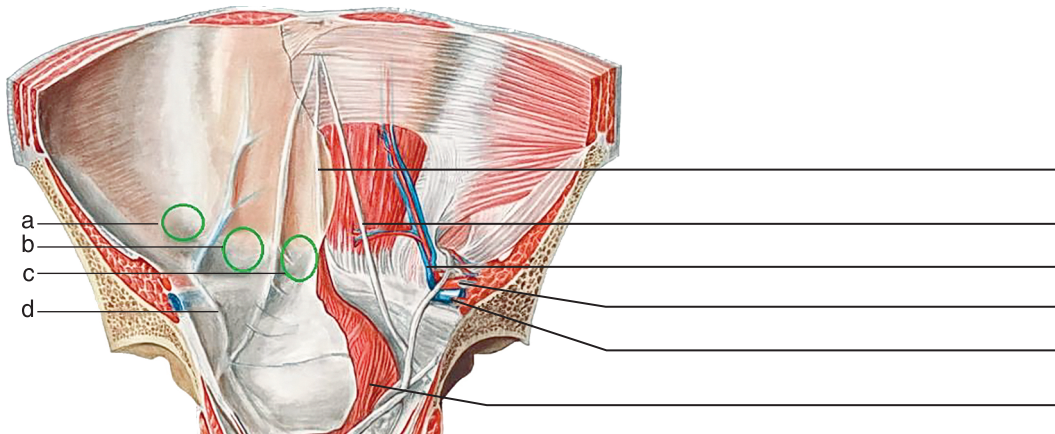


Fig. 13.6. Folds and recesses of the anterolateral abdominal wall

- a. _____
- b. _____
- c. _____
- d. _____

The deep inguinal ring corresponds to _____

The superficial inguinal ring corresponds to _____

13.7. Name the anatomical elements forming the inguinal canal in English and Latin using the Fig. 13.7. What structures form the superior, inferior, anterior and posterior walls of the canal?

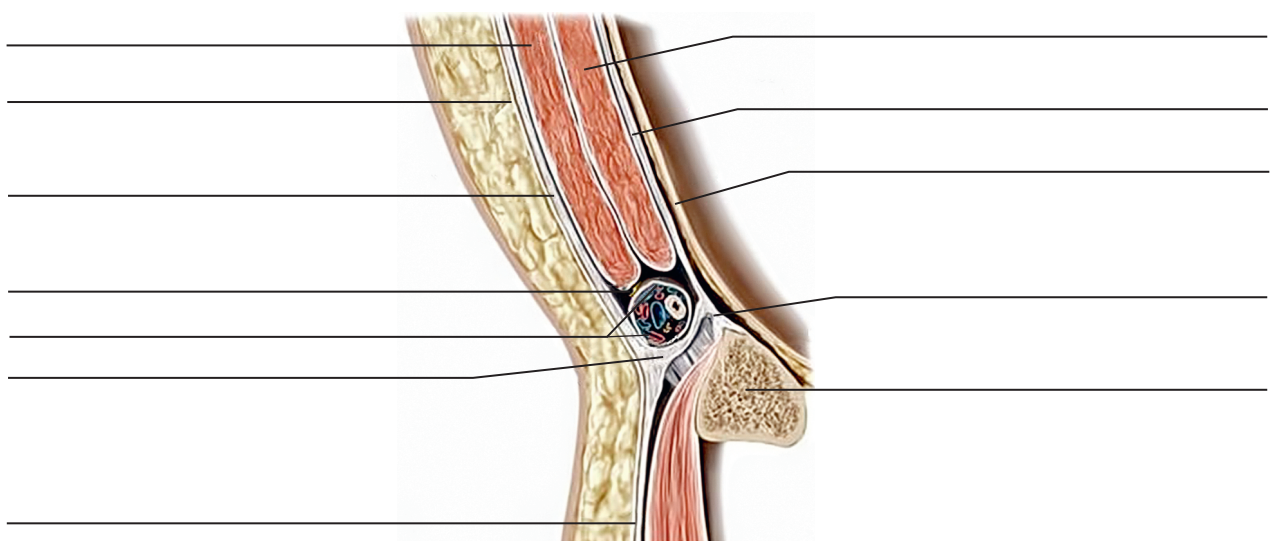


Fig. 13.7. Inguinal canal topography

The superior wall: _____

The inferior wall: _____

The anterior wall: _____

The posterior wall: _____

The content of the canal in males _____

The content of the canal in females _____

13.8. Sign the names of the anatomical structures involved in the formation of the femoral canal in the English and Latin, using Fig. 13.8. Specify, what structures form the deep and the superficial femoral ring and canal walls.

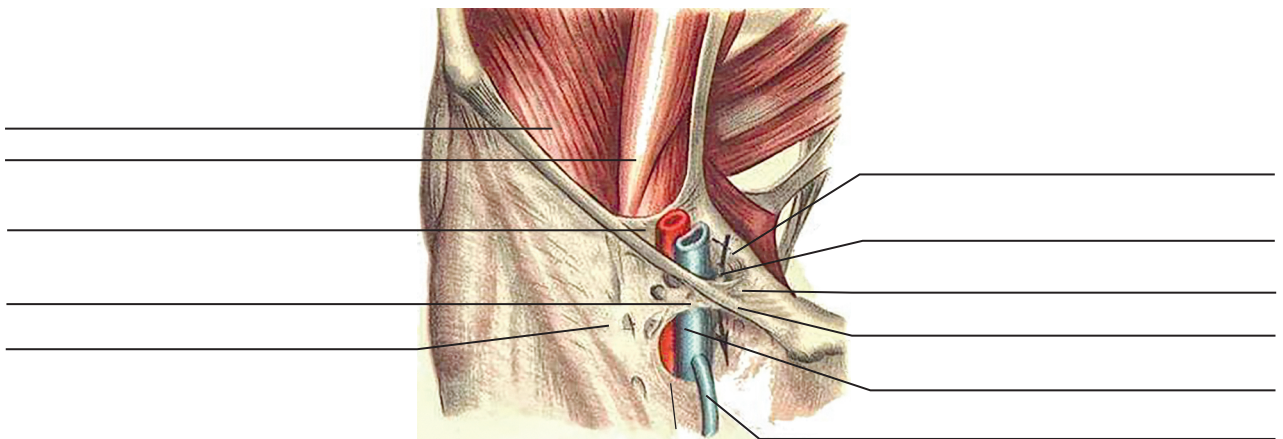


Fig. 13.8. Topography of the femoral canal

13.9. Explain the situation happened in this clinical case.

During the operational access to an inguinal hernia at the time of dissection of **subcutaneous adipose tissue**, arterial bleeding began. What artery was damaged?

14. TOPOGRAPHIC ANATOMY AND OPERATIVE SURGERY OF FEMORAL HERNIA AND HERNIAS OF THE ANTEROLATERAL ABDOMEN WALL

Topics of the lesson: Definition, classification, causes of external abdominal hernia. Hernia elements. Hernia classification. Surgical anatomy of hernia of the white line of the abdomen, umbilical, external oblique, straight, sliding congenital inguinal and femoral hernia. Postoperative hernia. Hernia repair: main stages, methods of inguinal hernioplasty (according to Bassini, Spasokukotsky, Girard, Kimbarovsky suture), umbilical hernioplasty (according to Lekser, Mayo, Sapezhko), abdominal white line hernia with own tissues and grafts. Features of operation technique for congenital, sliding, strangulated and postoperative hernia. Laparoscopic methods of inguinal hernioplasty. Features of hernia repair in children. Methods of the femoral hernioplasty.

14.1. Give the definition of a hernia and sign its elements shown in Fig. 14.1.

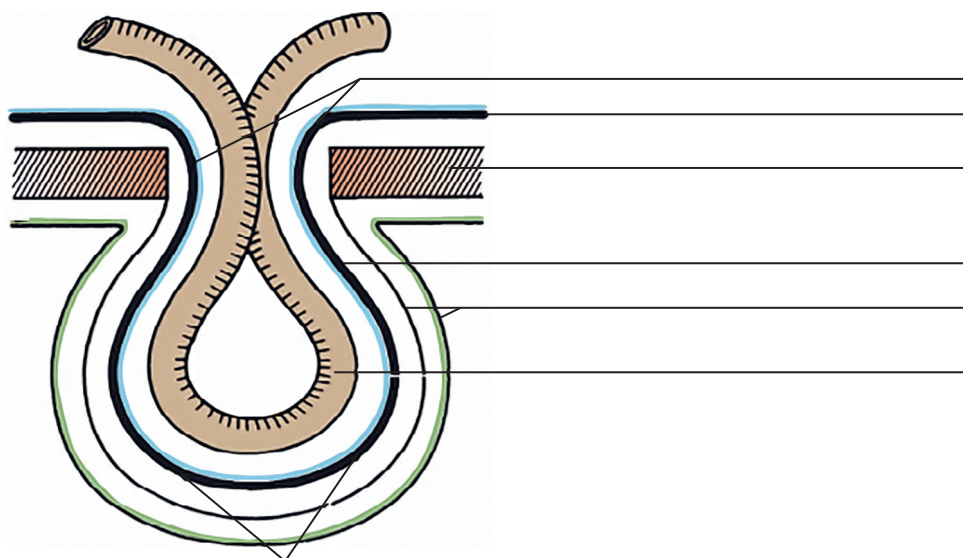


Fig. 14.1. Hernia elements

Hernia of the anterolateral abdomen wall is — _____

14.2. Using Fig. 14.2, name the borders of the inguinal triangle.

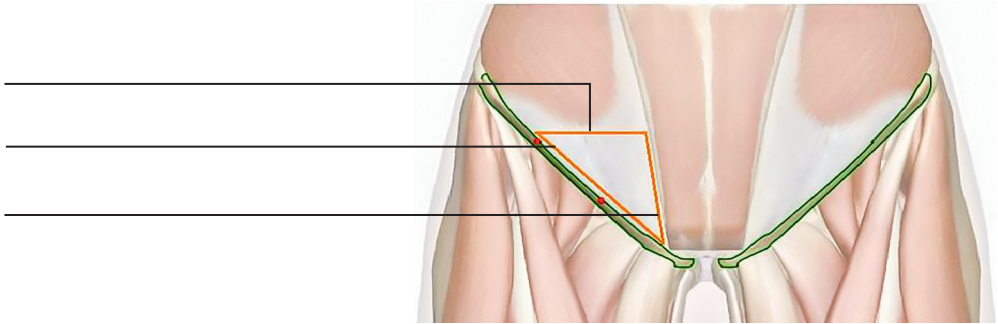


Fig. 14.2. Inguinal triangle

14.3. Using Fig. 14.3, name the walls of the inguinal space.

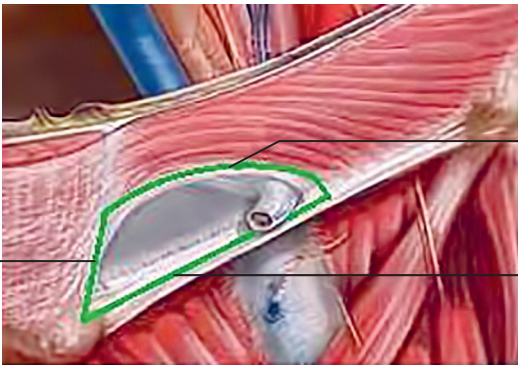


Fig. 14.3. Inguinal triangle

14.4. Fill the table «Anatomical classification of hernias». Sign the types of hernias shown in Fig. 14.4.

ANATOMICAL CLASSIFICATION OF HERNIAS	
EXTERNAL HERNIAS	INTERNAL HERNIAS

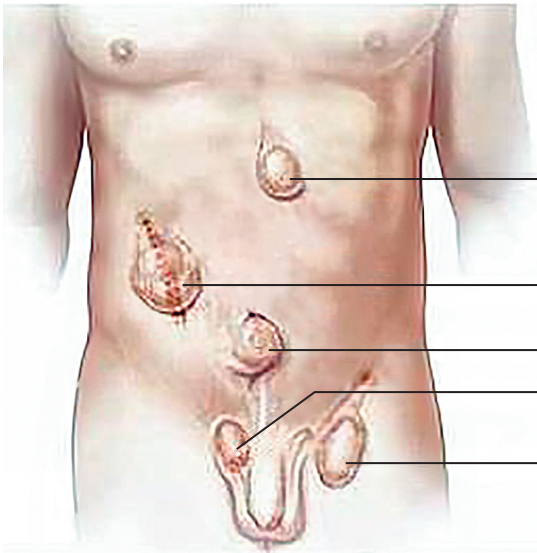


Fig. 14.4. Hernias of anterolateral abdominal wall

14.5. Write the stages of hernioplasty, using Fig. 14.5.

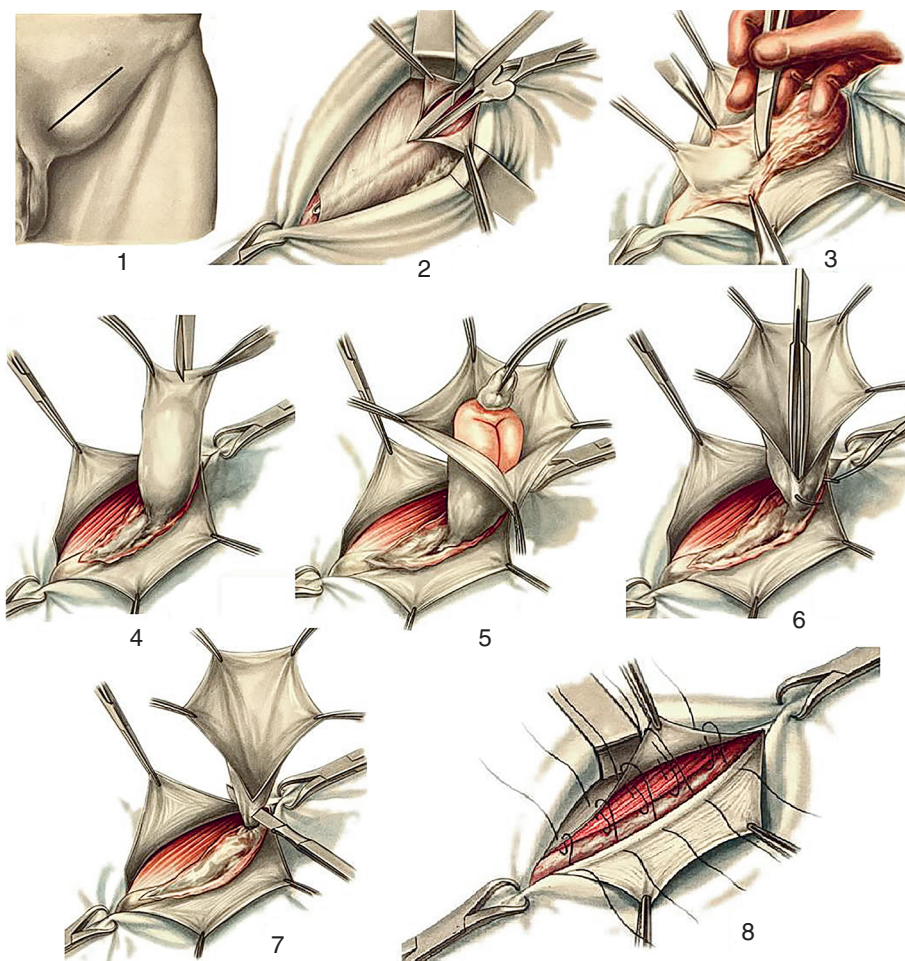


Fig. 14.5. Stages of hernioplasty

1. _____
2. _____

- 3. _____
- 4. _____
- 5. _____
- 6. _____
- 7. _____
- 8. _____

14.6. Guided by Fig. 14.6, name the testicular tunics and the layers of the anterolateral abdominal wall that form them.

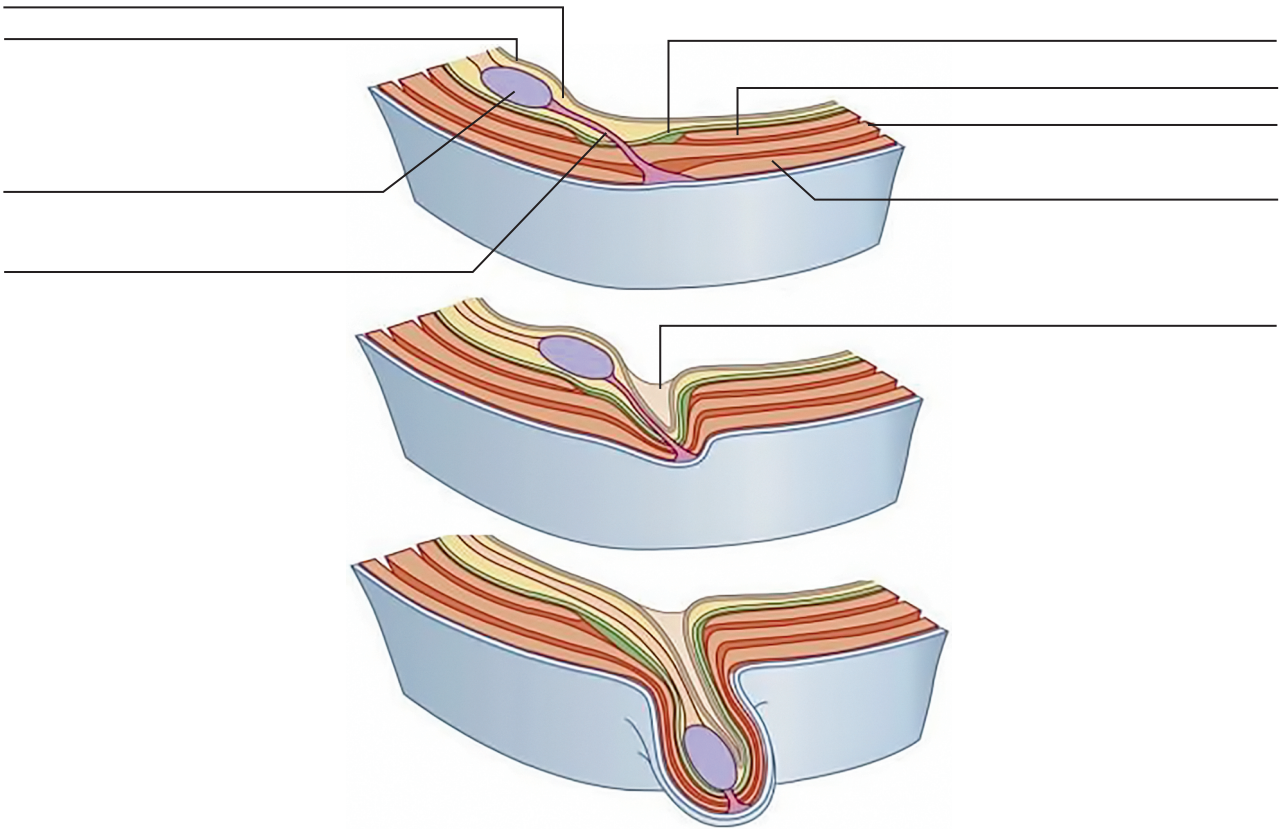


Fig. 14.6. Formation of testicular tunics

№	LAYERS OF THE ANTEROLATERAL WALL OF THE ABDOMEN	TESTICULAR TUNICS
1		
2		
3		
4		
5		
6		
7		

14.7. Using Fig. 14.7, write the distinctive features of indirect and direct inguinal hernias in the table.

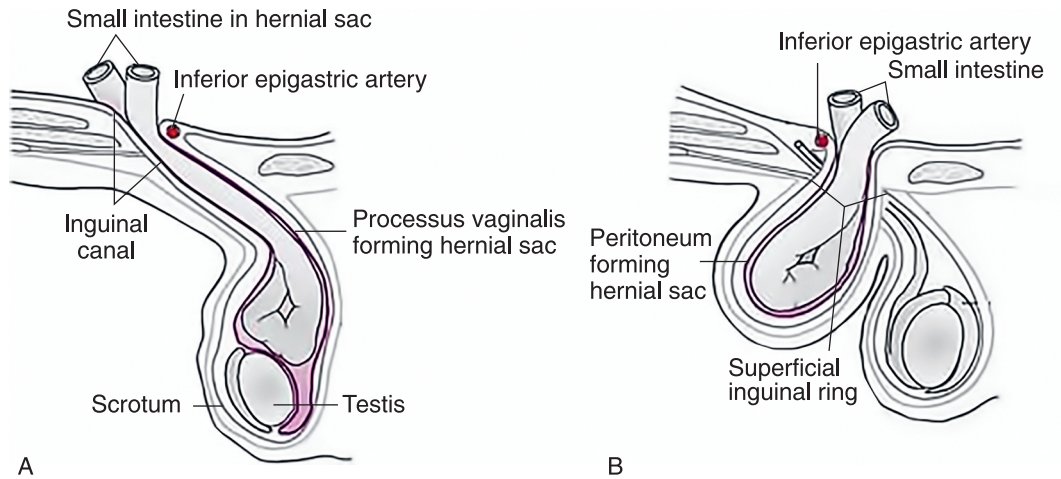


Fig. 14.7. The pattern of A — indirect and B — direct inguinal hernia formation

FEATURE	INDIRECT INGUINAL HERNIA	DIRECT INGUINAL HERNIA
Exit point		
Relation to the spermatic cord		
Opportunity to descend into scrotum		
Hernias bag relation to the inferior epigastric vessels		

14.8. Guided by Fig. 14.8, put the names of the anatomical elements involved in the formation of congenital (a) and non-congenital (b) inguinal hernia and explain their different.

PECULIARITIES OF THE CONGENITAL AND NON-CONGENITAL INGUINAL HERNIA	
CONGENITAL	NON-CONGENITAL

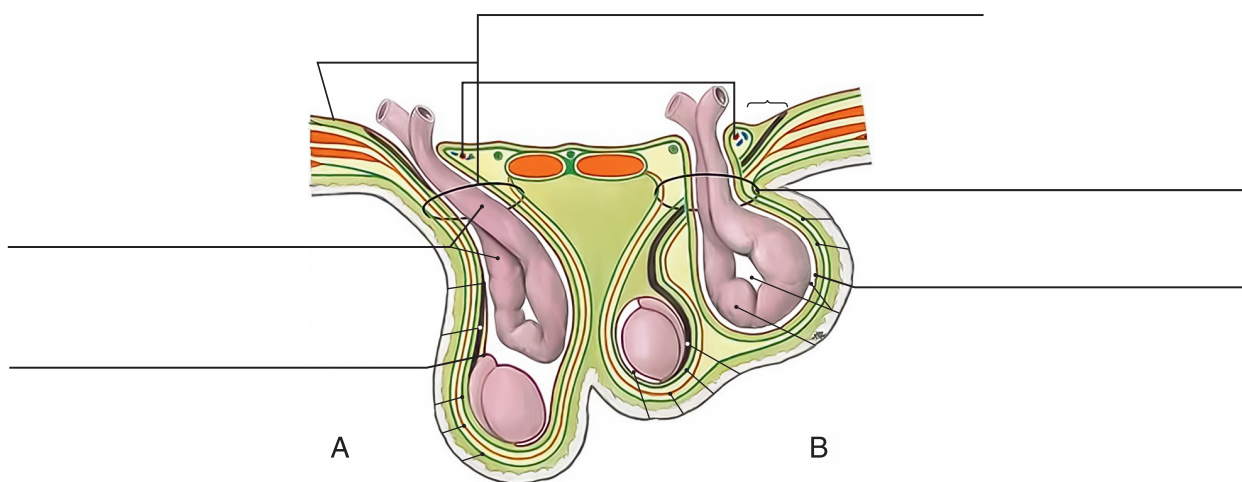


Fig. 14.8. Distinctive peculiarities of congenital and non-congenital inguinal hernia

14.9. In Fig. 14.9 A, write the anatomical structures. Highlight the Hesselbach's triangle. Which of the inguinal fossa corresponds to it? _____

What hernia is shown in Fig. 16.9 B? _____

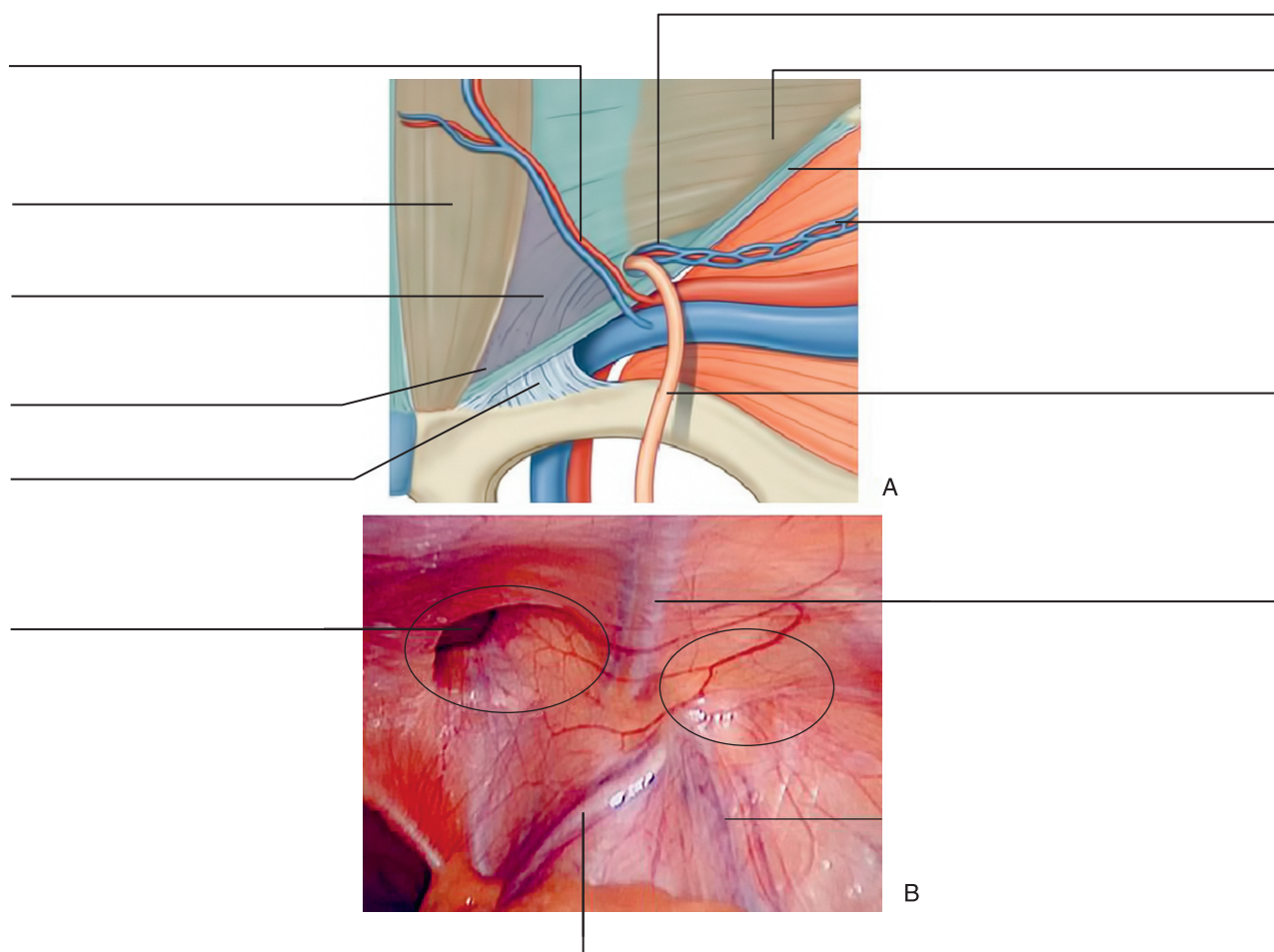


Fig. 14.9. Inside view of the anterolateral wall of the abdomen, a — scheme, b — laparoscopy view